

The 25th Annual

# Waltham/OSU Symposium

## Small Animal Ophthalmology

October 27 – 28, 2001

### Retinal Disease, Degeneration And Diagnosis.

---

Nicholas J. Millichamp, BVetMed, PhD, DVOphthal, MRCVS, Diplomate, ACVO.

*Dept of Small Animal Medicine and Surgery*

*College of Veterinary Medicine, Texas A & M University*

*College Station, TX.*

&

*Central Texas Veterinary Ophthalmology*

*Austin, TX.*

---

Diseases of the posterior segment or vitreous, retina, choroids, sclera and optic nerve (the fundus as seen through the pupil of the eye) are often poorly understood. Since many (especially the degenerations) have hitherto defied therapy, they assume a lesser significance than diseases of the anterior segment which are often more amenable to therapy in general practice. Nevertheless recognition of the cardinal signs of posterior segment disease can easily be mastered (using indirect ophthalmoscopy) and may give insights into conditions affecting vision or associated with other systemic maladies.

In considering the fundus we need to think of a number of superimposed layers of tissue (vitreous through sclera). Unlike almost any other tissue of the body (excepting the superficial skin layers), ophthalmoscopy allows examination of the layered tissues in detail. In general we need to keep in mind the concept of “**more or less**”. In inflammatory or neoplastic diseases the layered structures become thickened (‘more’) with infiltrates into one layer affecting the view of underlying structures. In degeneration we may see changes in appearance of a particular layer based on loss of tissue in an overlying tissue layer (‘less’). We are fortunate that our domestic species possess a tapetal layer since this makes the recognition of these pathologic processes much simpler than in atapetal species.

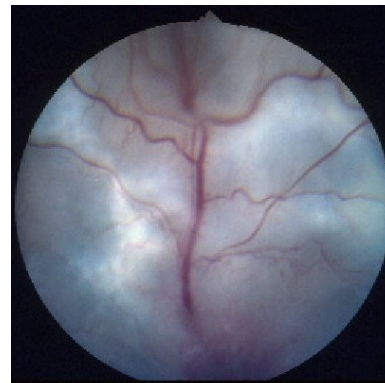
#### **Inflammation: Chorioretinitis, optic neuritis, retinal detachment.**

Lesions of the fundus consistent with inflammation and secondary neoplasia (primary neoplasia of posterior segment is rare) appear in the tapetal fundus as dark or gray (often fuzzy or out of focus) areas of opacification, which obstruct the view of the tapetum. Infiltrates (inflammatory cells, edema, neoplastic cells) may be in the vitreous, retina or between retina and retinal pigment epithelium, or located in the choroid (and hence tapetum itself). Small focal thickening of the retina may appear similar to thickening of the retina due to folding as seen in retina dysplasia.

Retinal blood vessels may be elevated or obscured by infiltrates. cuffing with light cellular infiltrates is well seen in the non-tapetal Hemorrhages may occur (especially vasculopathies like FIP, like rickettsial disease or associated with retinal ischemia in systemic hypertension). Sufficient subretinal exudates or transudates will cause elevation and detachment (occasionally see gray veil of retina and against posterior lens as leukocoria).

#### **Signs of retinal inflammation/neoplasia/hypertension/**

- Asymmetrical, irregular lesions
- Grey/dark often fuzzy opacities over the tapetum



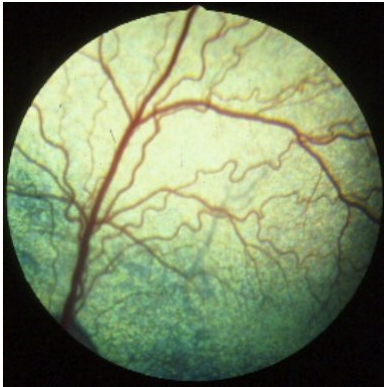
Perivascular  
fundus.  
coagulathies

retinal  
vessels

**detachment.**

- Tapetal color change
- Non-tapetal white/gray opacities (edema)
- Non-tapetal pigmentary changes
- Perivascular cuffing in non-tapetum
- Hemorrhage (pre-, intra- and subretinal)
- Retinal elevation/detachment (leukocoria)
- Edema/hemorrhage of the optic nerve

Changes of inflammatory nature must be distinguished from various inherited diseases, which may present with similar signs. **Retinal dysplasia** in several canine breeds (usually but not always present from birth) results in retinal folding,

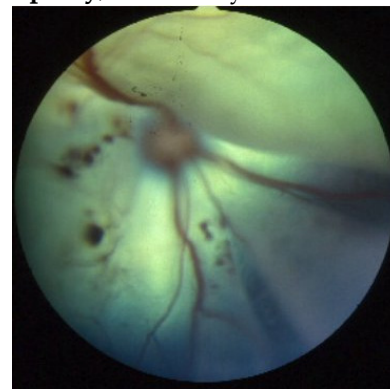

which may resemble multifocal areas of retinal edema. In severe cases retinal non-attachment or detachment may occur. **Collie eye anomaly** presents with congenital pigmentary changes in the fundus lateral to the optic disc. Additionally in more severely affected dogs colobomas of the optic nerve and retinal folding may result in retinal detachments and intraocular hemorrhage.

The causes of chorioretinitis largely parallel those, which were discussed in consideration of anterior uveitis. Infectious, immune mediated causes and neoplasms (usually metastatic) are commonly involved. As with anterior uveitis the presence of bilateral lesions sharply increases the suspicion of underlying systemic disease. Workup involves a thorough physical and ocular examination, minimum database, serology and/or PCR for infectious diseases, chest/abdominal radiographs and ultrasound, neurological examination, blood pressure measurement and aspirates or

biopsies from other affected tissues. Ultrasonography of the posterior segment is useful where opacities of the anterior segment media or lens obscure a view of the fundus. Aspirates from the posterior segment should be a last resort.

A specific retinopathy commonly seen in older cats is **hypertensive retinopathy**, which may occur secondary to hyperthyroidism, chronic renal failure, and adrenal neoplasia or occur disease. Cats typically present with a sudden onset of blindness by dilated non-responsive pupils. The retinas are often totally hemorrhage is common.



as primary accompanied detached and

Therapy of inflammatory type posterior segment disease should aim underlying cause wherever possible (e.g. in rickettsial, fungal or disease in dogs and cats. In some noninfectious conditions systemic hypertension in cats) medical therapy may be indicated to underlying systemic disease (hyperthyroidism, chronic renal failure) specifically reduce the ocular changes (reducing systemic blood calcium channel blockers, beta-blockers and ACE inhibitors). When tests have failed to reveal the presence of infectious agents or other diseases systemic corticosteroids at an immunosuppressive dose and other anti-inflammatory drugs (including cytotoxic agents such as azathioprine) are indicated to treat idiopathic chorioretinitis (assumed to be specific immune mediated retinal inflammatory diseases (uveodermatologic syndrome and immune mediated thrombocytopenia in dogs). Neoplasia affecting the posterior segment (lymphoma is perhaps the most common) is rarely amenable to effective long-term therapy.

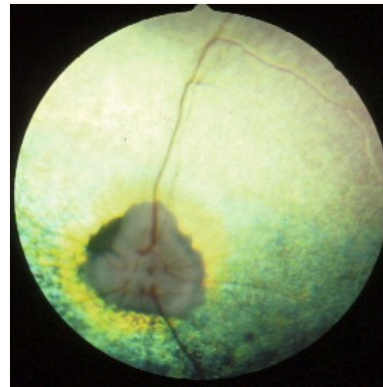
to treat the protozoal (particularly treat as well as pressure with all diagnostic underlying

Retinal detachments may occur in dogs and less commonly in cats which are unassociated with obvious inflammatory disease. In dogs various inherited congenital diseases (vitreoretinal dysplasia and collie eye anomaly) may predispose the retina to detachment. Some breeds (for instance the Bichon Frise) appear to be prone to retinal dialysis (disinsertion of the retina at the ora ciliaris retinae) and detachment. Cataract progression – particularly to the hypermature stage and/or cataract surgery are well known predisposing factors in the development of retinal tears and rhegmatogenous detachments (where the vitreous passes through a retinal tear and contributes to pushing the retina from the back of the eye. In some of these cases the extent of detachment can be limited (if caught early enough) by spot-welding (or creating a retinopexy) the retina to the underlying retinal pigment epithelium with an argon or diode laser. In more severe detachments it may be possible to perform scleral buckling or vitreoretinal surgery to repair the detachment. However often the detachments are severe enough once detected behaviorally by the owner that the prognosis for therapy is poor.

## Retinal degenerations

In retinal degeneration the lesions vary in appearance depending on location in the tapetal or non-tapetal fundus. Degenerative lesions in the tapetal fundus result in **thinning of the retina over the underlying tapetum**. There is consequently a greater amount of light reflected back to the observer in the thinned retina) (less absorbed

- Hyper-reflectivity over the tapetal fundus.
- This may be localized and asymmetric –often with development of increased pigmentation in areas of **inactive chorioretinitis**. Hyperreflectivity is generally bilaterally symmetrical and more diffuse in cases of inherited retinal degeneration (progressive retinal atrophy) or toxic retinal atrophy.
- Depigmentation and pigment clumping in the non-tapetal fundus (may be localized (post-inflammation) or diffuse (inherited, toxic)
- Narrowing of retinal blood vessels
- Atrophy of the optic nerve may accompany later stages of severe and often inherited retinal degenerations.

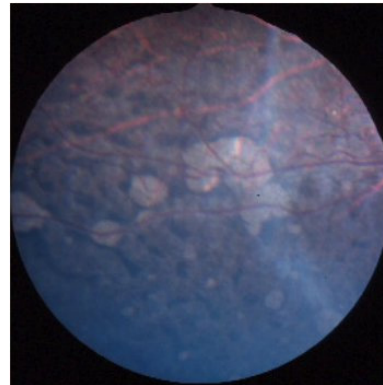


Various retinal degenerations occur in dogs and cats. Focal and diffuse degeneration may occur secondary to chorioretinitis and glaucoma respectively. The most important resulting in the loss of vision in the absence of other ocular signs fall three categories: degenerations into one of

- Inherited – progressive retinal atrophy in dogs and cats
- Idiopathic – sudden acquired retinal degeneration in dogs
- Toxic/nutritional – enrofloxacin toxicity and taurine deficiency in cats.

### *Progressive retinal atrophy*

Progressive retinal atrophy is a term used to encompass a large inherited degenerative diseases in many canine and some feline pure crossbreeds. Most of these conditions are inherited as autosomal recessive conditions (excepting X-linked PRA in the Siberian Husky and Samoyed and dominant PRA in the Mastiff). In Abyssinian cats both recessive and dominant forms of PRA occur. The biochemical abnormalities are understood in few of these diseases. groups of and



The diagnosis of progressive retinal atrophy is based (currently) on behavioral signs (especially night blindness) and the presence of the typical lesions described above. Clinically we broadly divide PRA into early and late onset forms depending on whether the signs develop in the first year of life or later in life. The electroretinogram (if stimulated correctly) may be useful in early diagnosis and in understanding the pathophysiology of the disease. More recently genetic testing of whole blood samples or frozen semen has become available. Optigen ([www.optigen.com](http://www.optigen.com)) based in Ithaca, NY has produced tests for Congenital Stationary Night Blindness in Briards and PRA (various types and genotypes) in various canine breeds (Table 1). The tests used in most of these breeds are **marker-based or linkage-based tests** which will reliably identify homozygous normal dogs. Since most are recessive diseases a proportion of the tested dogs are found to be carriers (but will not become affected with the disease themselves and a proportion are homozygous affected dogs which will develop the disease).

**Table 1.** Tests for inherited retinal diseases in dogs available from Optigen in June 2001.

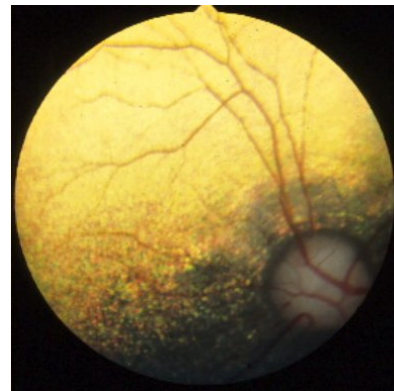
Briard  
 Cardigan Welsh Corgi  
 Chesapeake Bay Retriever  
 English Cocker Spaniel  
 Irish Setter  
 Labrador Retriever  
 Mastiff  
 Miniature Schnauzer  
 Poodle  
 Portuguese Water Dog  
 Samoyed  
 Siberian Husky  
 Sloughies

The tests used in some breeds (e.g. Irish Setter, Samoyed and Siberian Huskies are **mutation-based tests** which more accurately identify normal, carrier and affected dogs.

PRA varies considerably in its clinical appearance between and even within breeds. More than one genetic form of PRA occurs in some breeds (for instance poodles and miniature schnauzers) which complicates the genetic testing picture at present. Genetic diagnosis promises to facilitate eradication of inherited retinal diseases by enabling a diagnosis at a much earlier age than currently possible clinically or by electroretinography.

***Sudden Acquired Retinal Degeneration (SARD)***

SARD is a canine disease of unknown etiology. The presenting sign is of blindness (often over a few days). Usually at examination the totally blind although the PLR may be present. The fundus (and entire eye) initially looks normal in most (but not all) cases. The diagnosis includes optic neuritis (for instance in GME), pituitary blindness (related to neoplasia). SARD is easily differentiated from conditions with an electroretinogram which is extinguished in SARD the other conditions which do not involve the retina. We know of no prevent this disease at present and there is no therapy.

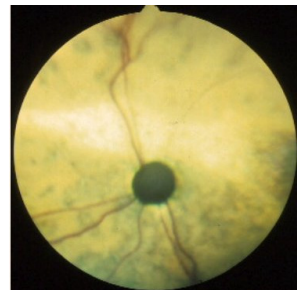

a rapid onset animal is actually the differential tumor or CNS these other but normal in way to

***Retinal degenerations in cats (taurine, PRA, enrofloxacin)***

PRA also occurs in cats – the biochemical defect in one form of PRA in Abyssinian cats is the same as in Irish Setters. Late and early onset forms of PRA have been reported in the Abyssinian. PRA also occur in Persians and sporadically has been reported in other breeds. The clinical appearance is similar to dogs, although cats will often compensate behaviorally to a much greater extent than dogs.

Nutritional deficiency of taurine results in feline central retinal degeneration typical band like lesions of tapetal hyperreflectivity in the central retina above the optic disc. With progression of the disease the entire fundus becomes is then indistinguishable from any other causes of diffuse retinal. Affected cats should be monitored for dilated cardiomyopathy. FCRD is seen commonly in recent years since supplementation of feline diets with taurine.



(FCRD) with the level of affected and degeneration. less

Enrofloxacin has recently been associated with retinal degeneration in cats at recommended dose rate. Affected cats present with rapid onset of blindness enrofloxacin administration. Affected cats have typical lesions of retinal. Discontinuation of enrofloxacin as soon as visual problems are noted may result in improvement in vision in some, but not all cases. No doubt guidelines will be forthcoming regarding the use of enrofloxacin in cats in view of increasing numbers of anecdotal adverse reaction reports as well as published data or its potential toxicity.

the after systemic degeneration.

**Further Reading**

Narfstrom, K, Ekestén, B: Diseases of the canine ocular fundus. In: Veterinary Ophthalmology, ed, Gelatt, KN, 1999 (3<sup>rd</sup> ed). Baltimore, Lippincott, Williams and Wilkins. 869-933  
 Barnett, KC and Crispin SM: Feline Ophthalmology, An Atlas and Text 1998, London, W.B.Saunders Company.

Glaze, MB, Gelatt, KN: Feline Ophthalmology. In: *Veterinary Ophthalmology*, ed, Gelatt, KN, 1999 (3<sup>rd</sup> ed). Baltimore, Lippincott, Williams and Wilkins. 997-1052

Copyright © 2001

**Waltham USA, Inc.**

All rights including that of translation into other languages, reserved. Photomechanical reproduction (photocopy, microcopy) of this publication or parts thereof without written permission from Waltham USA, Inc. is prohibited.

The opinions expressed in these proceedings are those of the authors and not necessarily those of Waltham.

Additional copies can be obtained from Waltham USA, Inc. The proceedings may also be found online at the WALTHAM® web site at <http://www.walthamusa.com> or the VIN web site at <http://www.vin.com/OSUWaltham/2001/>.

Designed and published by Veterinary Information Network (VIN).