

The 25th Annual

Waltham/OSU Symposium

Small Animal Ophthalmology

October 27 – 28, 2001

Diagnostic and Therapeutic Approach to Orbital Disease in Dogs and Cats

David T. Ramsey, DVM, Diplomate ACVO
*Associate Professor, Comparative Ophthalmology,
Department of Small Animal Clinical Sciences
D-208 Veterinary Medical Center
Michigan State University
East Lansing, MI 48824-1314*

Orbital disease is common in dogs and cats but is frequently misdiagnosed and subsequently may be treated inappropriately. A general review of normal orbital anatomy is necessary to understand disease processes affecting the orbit.

Anatomy

Orbital Osteology

The bony orbit in dogs and cats is classified as incomplete or open because it is encompassed incompletely by bone. Components of the bony orbit include the frontal lacrimal, zygomatic, presphenoid, basisphenoid, and palatine bones. Only the medial wall, the medial aspect of the roof (dog) and entire roof (cat), and the rostral orbital rim excluding its lateral boundary are osseous. The rostral orbital rim is osseous for four-fifths of its circumference and is comprised by the maxilla, frontal, lacrimal, and zygomatic bones. The rostral orbital rim is completed by the orbital ligament which extends from the zygomatic process of the frontal bone to the frontal process of the zygomatic bone. The medial orbital wall is formed by the pars orbitalis of the frontal bone, a thin septa that separates the orbit from the nasal cavity. The optic canal and orbital fissure of the sphenoid bones define the caudal orbital apex.

Orbital Soft Tissues

The orbit is a restricted trapezoidal cavity that is composed primarily of soft tissue structures. The globe, ocular adnexal structures, and glandular, vascular, nervous, and adipose tissues are the major tissues within the orbit. Muscles of mastication define the boundaries of the ventral, caudomedial, and caudolateral orbit. The caudomedial orbit is bounded by the temporalis muscle and frontal bone. The caudal and lateral boundaries of the orbit are composed of the masseter muscle, vertical ramus of the mandible, and the zygomatic arch. The zygomatic salivary gland lies on the dorsolateral surface of the medial pterygoid muscle in the dog and forms most of the orbital floor. The medial third of the orbital floor is composed of the medial pterygoid muscle and orbital fat. The lateral pterygoid muscle contributes minimally to the caudoventral orbital floor. The pterygopalatine ganglion and nerve, palatine nerves, maxillary artery, and maxillary branch of the trigeminal nerve traverse the floor of the orbit obliquely between the dorsal surface of the medial pterygoid muscle and the ventral surface of the zygomatic salivary gland. The orbital septum, a dense, fibrous connective tissue sheath, marks the rostral boundary of the orbit.

Orbital Compartments

The orbit may be broadly divided into three anatomical compartments: intraconal (within the endorbital muscle cone); extraconal (outside the endorbital muscle cone but within the soft tissue confines of the orbit; and extraendorbital (beneath the periosteum). Intraconal and extraconal spaces are separated by radial fibrous connective tissue septa called endorbita. Intraconal structures include the extraocular muscles, cranial nerves II, III, IV, V₁ (ophthalmic branch of the trigeminal nerve), VI, autonomic nerves, orbital lacrimal gland, arteries and veins, smooth muscle, and fat. When

determining which anatomical compartment of the orbit is affected, observe the direction of displacement of the globe/orbital structures. Intraconal mass lesions result in axial exophthalmos but infrequently cause elevation of the nictitating membrane unless substantial intraconal mass effect is present. Extraconal mass lesions almost always result in protrusion of the nictitating membrane. Strabismus and/or displacement of the globe is usually opposite in direction to the location of the mass. Clinical signs attributable to mass lesions located outside the endorbita may mimic those of extraconal masses but usually are associated with nasal or paranasal sinus disease.

Neighboring Orbital Structures

The nasal cavity and paranasal sinuses are directly adjacent to the medial orbit. The roots of caudal maxillary teeth and the location of the tooth roots in relation to the orbit differ based on skull conformation. Tooth roots of the maxillary fourth premolar tooth and the first and second molar teeth are in close proximity to the orbital floor. Brachycephalic dogs have orbits that are shallow and located more rostral to the caudal maxillary teeth compared with orbits of mesaticephalic or dolichocephalic breeds. Only a thin layer of alveolar bone separates the roots of the caudal maxillary teeth from soft tissues of the orbital floor. Dental disease is a common cause of orbital inflammation in dogs and cats.¹

Diagnostic Approach to Orbital Disease

I. History

A thorough history and physical examination are prerequisites to the diagnostic work-up of all ophthalmic and orbital abnormalities. A complete history will often provide valuable information regarding the type of orbital disease affecting an animal. When orbital disease is suspected, history should always include a determination of the onset and duration of the abnormality, change in eating behavior, difference in temperament/behavior, and change in visual performance.

II. Examination

Since orbit is a confined space, it has no room for expansion or enlargement of its contents. The orbit cannot be examined directly and signs of orbital disease are evident only indirectly. Orbital disorders are characterized by clinical signs that alter the function, appearance, or position of the globe, eyelids or ocular adnexal structures. Compare the size of palpebral fissures, observe eyelid carriage, position of eyelids and nictitating membrane, location and mobility of the globe within the orbit, and the presence of ocular discharge. The following should be done when orbital disease is suspected:

- 1) Palpation of the periocular/periorbital areas.
- 2) Retropulsion of the globe into the orbit through the closed eyelid. The globe can be retropulsed if there are no space occupying lesions in the orbit.
- 3) Careful examination of the oral cavity. Periodontal/dental examination with general anesthesia (periodontal probe/dental explorer). When dental disease is not immediately evident, dental radiographs should be made.
- 4) Aural examination.
- 5) Neuro-ophthalmic examination

A. Primary and Secondary Clinical Signs of Orbital Disease

Clinical signs of orbital disease are divided arbitrarily into primary and secondary categories (Table 1). Primary signs are referable only to the globe-orbit relationship and denote three-dimensional changes in position, placement, or alignment of the globe within the orbit. There are three primary signs of orbital disease: Exophthalmos, enophthalmos and strabismus. Exophthalmos (Figure 1A and B) and enophthalmos (Figure 2). are used to describe anterior and posterior displacement of the globe along the orbital axis. Strabismus is the term used to describe involuntary deviation of the globe from the normal optical axis (Figure 3). Displacement (shift) of the globe from its normal position may also occur in the horizontal (lateral, medial) or vertical (dorsal, ventral) meridian or a combination thereof (oblique) direction. Oblique shifts in position are designated as a combination of the two directions in which the globe is displaced (e.g., dorsolateral oblique displacement). Secondary signs of orbital disease occur as a result of exophthalmos, enophthalmos, strabismus, or shift. Secondary signs include changes in anatomy or function of the globe, eyelids, orbital structures, or surrounding tissues. These include alterations in vision, ocular movements, eyelid and nictitating membrane position, pupillomotor function, sensation (pain or numbness), globe indentation, vascular engorgement (conjunctiva, episclera, fundus), corneal or conjunctival exposure, and pain during (or limitation of) mandibular excursion.

Secondary clinical signs include (not all-inclusive):

- | | |
|--|-------------------------|
| 1) conjunctival hyperemia | 7) lagophthalmos |
| 2) chemosis | 8) exposure keratitis |
| 3) swelling of lids and periorbita | 9) abnormal PLR's |
| 4) elevation of the nictitating membrane | 10) visual impairment |
| 5) pain upon opening the mouth | 11) scleral indentation |
| 6) mild increase in IOP (NOT glaucoma) | 12) facial asymmetry |

III. Classification Of Orbital Disease

When clinical signs of orbital disease are present, an attempt should be made to classify the disease process into inflammatory, neoplastic, or cystic categories. These three categories constitute the most common orbital diseases in dogs and cats.

A. Inflammatory

Inflammatory orbital disease may occur at any age and rapid onset and progression of clinical signs typify orbital inflammation. Historical findings may include refusing to eat dry dog/cat foods, anorexia, weight loss, and change in behavior or temperament. Resistance to opening the mouth (indicative of pain) or overt signs of pain when the mouth is opened, or during palpation of the periorbital area or retropulsion of the globe may be evident. The coronoid process of the mandible impinges on the orbital tissues when the mouth is opened. Fever and leukocytosis may also be evident.

B. Neoplastic

Orbital neoplasia generally affects older animals (mean age for dogs 8 years,² mean age for cats 8.9 years³), causes slowly progressive clinical signs over a period of weeks to months, and usually does not cause pain until the neoplasm is of considerable size. The exceptions to this general rule include mast cell sarcoma, lymphoma, and any neoplasm that has rapid growth characteristics that exceeds its nutritional [blood] supply and subsequently undergoes necrosis.

C. Cystic

Cystic orbital disease may have an insidious or rapid onset of clinical signs and pain is usually absent or minimal. Age of animal is variable. Orbital cysts are derived from epithelial or glandular tissue within or surrounding the orbit (lacrimal glands, salivary glands, conjunctival, oral, nasal, or sinus epithelium). Cysts may occur if glandular or conjunctival tissue is resected incompletely during enucleation surgery.

IV. Diagnostic Testing

When orbital disease is suspected, diagnostic test should include a CBC and serum biochemical profile. Cytologic examination of fine needle aspirates from the retrobulbar space, radiographs, and cross-sectional imaging techniques (orbital echography, CT, MR imaging) may be indicated prior to surgical planning. Contrast orbital imaging techniques may also be of value when cross-sectional imaging techniques are not readily available.

V. SELECTED ORBITAL DISEASES

A. Orbital Cellulitis/Abscess

Tooth root abscesses from periodontal or endodontic disease constitute the most common causes of orbital cellulitis/abscess in dogs and cats.¹ Trauma, foreign bodies, extension of sinusitis, bone sequestration, oral foreign bodies (animal chewing on bones/sticks, etc) may also result in orbital abscess. It may also occur from hematogenous, transscleral, or transmucosal (conjunctiva, oral, nasal) injury or disease resulting in inoculation of the orbital space with infectious organisms. Onset of clinical signs is usually rapid. Clinical signs include fever, pain upon opening mouth, chemosis, conjunctival hyperemia and exophthalmos (Figure 4). Leukocytosis may be evident on CBC. Making a distinction between orbital abscess and cellulitis based only on clinical signs and physical examination is virtually impossible. Ultrasound of the orbit frequently may differentiate orbital cellulitis from abscess. Diffuse orbital cellulitis produces a generalized loss of definition of the orbital tissues, resulting in loss of definition of the optic nerve and extraocular muscles when compared with the opposite eye. Cellulitis may also produce focal mass lesions that may be

mistaken for a neoplasm. Abscesses are variable in appearance but most are recognized as a hypoechoic area within a well-defined hyperechoic wall (Figure 5). The abscess wall may not be seen with ultrasound in all instances. A soft, fluctuant swelling present behind the last molar is considered typical (in the literature) of retrobulbar abscesses, but is actually infrequently present. Periodontal or endodontic diseases of the maxillary PM3, PM4, M1, and M2 can cause orbital or periorbital disease. Effective treatment consists of establishing surgical drainage, local irrigation, and systemic antibiotics. The recommended diagnostic tests for a suspected orbital abscess include orbital echography, oral examination with a dental explorer and periodontal probe, and dental radiography. If test results reveal dental disease, drainage should be established by extracting the affect tooth and allowing drainage to occur through the alveolus (NOT by creating an incision caudal to the maxillary second molar tooth). When dental disease has been eliminated as the cause of the abscess, transmucosal surgical drainage may be done using ultrasound to select the most appropriate surgical approach. Most frequently a small incision is made in the oral mucosa caudomedial to the maxillary second molar tooth. A sterile blunt instrument is then introduced into the incision and forced gently through the medial pterygoid muscle using a short finger stop so that damage to the globe does not occur. Culture and susceptibility testing should be submitted if purulent material is drained. It is not necessary to blindly irrigate the orbital space after establishing drainage. Antibiotics (amoxicillin/clavulanic acid) should be administered orally and exposure keratitis or iridocyclitis treated if present. The wound should not be sutured, but left to heal by second intention healing.

B. Masticatory Muscle Myositis

Masticatory myositis occurs most commonly in Shetland sheepdogs, German Shepherds, Golden Retrievers, and Weimaraners, but any other canine breed may be affected. This disease has not been reported in cats. The disease involves the masseter, temporalis and pterygoid muscles (i.e., muscle of mastication – those muscles innervated by V3). Cellular and humoral mediated destruction of type IIM myofibers (common to masticatory muscles) is thought to cause masticatory myositis. Mean age of affected dog is 3 years and male and female dogs are affected equally.⁴ Clinical signs of the acute form of the disease include exophthalmos (uni- or bilateral), eyelid edema, protrusion of the third eyelid, conjunctival hyperemia (Figure 6), and pain upon opening the mouth. Masseter and temporalis muscles are typically swollen, firm to the touch, and signs of pain are elicited upon rigid palpation. The medial pterygoid muscle may also be palpated through the roof of the mouth caudal and medial to the maxillary dental arcade. Acute inflammation may last 10-21 days and frequently recurs. Chronically affected dogs may have trismus and atrophy of the temporalis and masseter muscles (Figure 7), resulting in enophthalmos and elevation of the nictitating membrane. Histologic examination of temporalis muscle (biopsy) tissue shows lymphocytic infiltration and type IIM myofiber antigen-antibody complexes. Serum may be submitted for analysis (antibodies directed against type IIM myofibers) if muscle biopsy is not possible (Dr. Diane Shelton, Comparative Neuromuscular Laboratory, 619-534-1537). Treatment consists of administration of immunosuppressive doses of corticosteroids (2 mg/kg q 12 h) for a minimum of 21 days prior to decreasing the dosage. Although clinical response to treatment may be dramatic in 3-5 days, decreasing the dosage prior to 21 days is associated with a high rate of recrudescence. After the initial dosage, the dosage should be decreased slowly over the next 2 months. Azathioprine (2 mg/kg, PO q 24 hours) may also be effective. When trismus is present, a gruel diet should be offered.

C. Extraocular Polymyositis

Extraocular polymyositis is a recently described disease affecting Golden Retrievers, Dobermans, Springer Spaniels and other canine breeds.⁵ Extraocular polymyositis is a rare, immune-mediated inflammatory myopathy that is limited to the extraocular muscles in dogs. Eighty percent of dogs are between 7-10 months of age (median age of 8 months) and females are affected most frequently. An antecedent “stressor” (ovariohysterectomy, estrus, and castration, boarding at a kennel) occurred within 14 days of the onset of clinical signs in 43% of affected dogs. The disease is primarily bilateral but not necessarily symmetrical. Acute onset of axial exophthalmos, chemosis, 360° scleral show, retraction of the upper eyelid, and lack protrusion of the third eyelid (Figure 8). Signs of pain are absent. There may be moderate resistance to retropulsion of the globe and vision may be compromised. Diagnosis is based on clinical signs, results of C T or MR imaging, and extraocular muscle biopsy. The mononuclear cell infiltrate of extraocular muscles is composed primarily of CD3+ T lymphocytes and macrophages directed against fine extraocular myofibers. Treatment is the same as for masticatory myositis (see above). A high rate of recurrence is reported with subsequent physiologic stressors (heat cycles, boarding at kennels, etc).

D. Orbital Neoplasia

Signs of orbital neoplasia usually progress slowly and may be insidious in evolution to evade perception until the disease is considerably advanced (Figure 1). Neoplastic orbital diseases of dogs and cats have had a poor prognosis that has been attributed to the late presentation of affected animals for treatment and malignant character of orbital neoplasms.

Primary neoplasms constitute the majority of orbital neoplasms in dogs, whereas secondary neoplasms are most frequently reported in cats. Ninety one percent of orbital neoplasms in dogs and 90% in cats are histologically classified as malignant.^{2,3} The most common clinical sign is slowly progressive unilateral exophthalmos. Pain is not a consistent clinical sign upon opening the mouth, and fever or leukocytosis are usually absent. However orbital neoplasia may masquerade as inflammatory orbital disease.⁶ Orbital lymphoma and mast cell sarcoma are neoplasms that are characterized by rapid onset and cause pain. These two neoplasms may also affect animals at fairly young ages. The average age at diagnosis of orbital neoplasia for dogs and cats is 8 and 8.9 years, respectively.^{2,3,6} Orbital ultrasound, fine needle aspirate, skull radiographs, CT scan, MRI, thoracic and abdominal radiographs are indicated prior to exploratory orbitotomy for biopsy. Adjuvant treatment depends on the type of neoplasm, extent of involvement, and whether or not metastases are present. Whenever orbital surgical intervention is considered, the surgeon should:

- 1) Ascertain the type of neoplasm (fine-needle aspiration and biopsy, biopsy)
- 2) Determine the extent of the neoplasm (define boundaries)
- 3) Be completely familiar with orbital anatomy
- 4) Anticipate surgical or postoperative complications
- 5) Realign any unrealistic expectations the client may have

E. Cystic Orbital Disease

Cystic orbital disease may arise from any epithelial or glandular tissue within the orbit or surrounding (neighboring) tissue (orbital lacrimal gland, gland of the nictitating membrane, zygomatic salivary gland, mucosa of the paranasal sinuses), or from retained or buried conjunctival mucosa (eg, post-enucleation). Cysts appear as a pale gray-blue color when transilluminated, are usually firm and smooth, and have a distinct plane between normal orbital tissues and the external cyst wall. A cyst may also appear as a fluctuant swelling beneath the lower eyelid, palpebral conjunctiva, or as a protrusion beneath the oral mucosa caudal to the maxillary molar teeth. Occasionally a cyst may dissect spontaneously into the oral cavity or the conjunctival fornix.⁷ Mucocele is usually non-painful or minimally painful, however clinical signs of pain similar to sialoadenitis may be present if mucocele has associated inflammation. Polystomatic openings of the zygomatic salivary ducts should be examined for redness and swelling, and the character of the fluid exuding from the openings noted. Ultrasonographically, a cyst appears hypoechoic or anechoic and well-delineated from surrounding tissues. Upon aspiration, cyst contents may be serous or highly viscous and clear or rust-colored.

Dogs and cats with zygomatic sialoadenitis exhibit signs of pain when the mouth is opened, and may or may not have swelling along the side of the face ventral to the palpebral fissure. A thick, tenacious, mucoid saliva may emanate from the zygomatic salivary papillae. Orbital ultrasound is useful to differentiate mucocele (hypoechoic or anechoic cavity) from sialoadenitis (diffuse hyperechogenicity). Surgical removal of zygomatic mucocele by orbitotomy is recommended in contemporary surgical textbooks, but treatment with a broad-spectrum antibiotic usually results in resolution of zygomatic mucocele in many instances. Culture and susceptibility testing of material collected from mucocele (aspirate) and sialoadenitis (collected from zygomatic papillae) should be done. Surgical intervention may be necessary when clinical signs do not improve within several days of medical treatment. Zygomatic sialoadenitis should also be treated with a broad-spectrum antibiotic. Topical treatment with an ophthalmic ointment should be done when exophthalmos is present in an attempt to prevent exposure and desiccation. When surgical excision is done, cystic tissues should be examined histologically to detect cystic neoplasms of orbital tissue origin.

References

- Ramsey DT, Manfra Marretta S, Hamor RE, Gerding PA, Knight B, Johnson JM, Bagley LH. Ophthalmic manifestations and complications of dental disease in dogs and cats. *J Am Anim Hosp Assoc* 32:215-224, 1996.
- Gilger BC, McLaughlin SA, Whitley RD, et al. Orbital neoplasms in cats: 21 cases (1974-1990). *J Am Vet Med Assoc* 201:1083-1086, 1992.
- Kern TJ. Orbital neoplasms in dogs. *J Am Vet Med Assoc* 186:489-491, 1995.
- Gilmour, MA, Morgan RV, Moore FM. Masticatory Myopathy in the Dog: A Retrospective Study of 18 Cases. *J Am Anim Hosp Assoc* 28:300-306, 1992.
- Ramsey DT. Exophthalmos. In *Kirk's Current Veterinary Therapy XIII Small Animal Practice*. Ed by JD Bonagura. Philadelphia, WB Saunders, 2000, pp 1086-1089.
- Hendrix DVH, Gelatt KN. Diagnosis, Treatment and Outcome of Orbital Neoplasia in Dogs: A Retrospective Study of 44 Cases. *J Small Anim Prac* 41:105-108, 2000.
- Ramsey DT, Fox DB. Surgery of the Orbit. *Veterinary Clinics of North America (Small Animal Practice)*, Philadelphia, W.B. Saunders, 27:1215-1264, 1997.

Table 1. Several orbital diseases causing exophthalmos, enophthalmos, and strabismus.

Exophthalmos	Enophthalmos	Strabismus
<i>Congenital (brachycephalic)</i>	<i>Congenital (dolichocephalic)</i>	<i>Congenital (brachycephalic)</i>
Abscess/cellulitis (bacteria, fungi)	Pain (active retraction)	Proptosis/MR avulsion
Neoplasia (1° or 2°)	Neoplasia (1° or 2°)	Masticatory myositis (acute)
Trauma	Horner's syndrome	Extraocular polymyositis
Zygomatic mucocele/sialoadenitis	Anorexia/dehydration	Zygomatic mucocele
Bleeding (platelet) disorders	Chronic inflammation	Trauma/orbital fractures
Clotting disorders (coagulopathy)	Atrophy of orbital tissues	Neoplasia (1° or 2°)
Masticatory myositis (acute)	Masticatory myositis (chronic)	Lacrimal cyst
Extraocular polymyositis	Orbital fractures	Hydrocephalus
Cranio-mandibular osteopathy	Phthisis bulbi	
Varix/vascular anomaly	Microphthalmos	
Proptosis	Varix/vascular anomaly	

Figure Legends

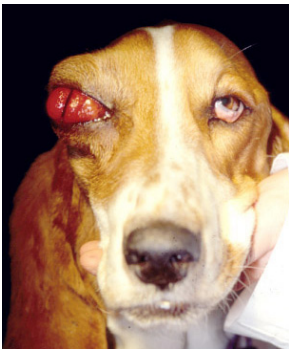

Fig 1A



Fig 1B

Figure 1. Exophthalmos. *A* – Severe exophthalmos and dorsolateral displacement of the right globe is evident in the 4-year-old Basset hound with an orbital sarcoma. The third eyelid is protruding and severe chemosis is present. *B* – Bart Simpson with classical signs of bilateral exophthalmos



Figure 2. Enophthalmos. Bilateral enophthalmos is present in this Boxer dog with tetanus. Both third eyelids are protruding excessively in response to retraction of the globes.



Figure 3. Strabismus. Strabismus and ventrolateral displacement of the left globe is present in this 3-year-old male cat. The pars orbitalis of the frontal bone was fractured as a result of automobile trauma.

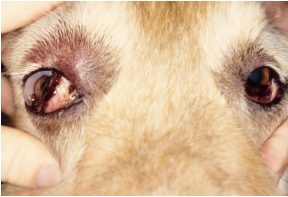

Figure 4. Clinical signs of an abscess of the right orbit. Substantial chemosis, conjunctival hyperemia, exophthalmos, blepharedema, and elevation of the third eyelid are evident in this Golden Retriever with an orbital abscess. The abscess was attributable to a root abscess of the maxillary 4th molar tooth.

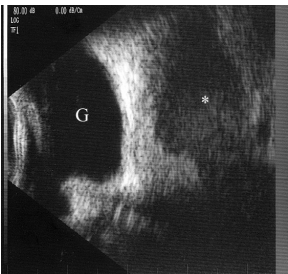

Figure 5. Ultrasound image of an orbital abscess in a dog. Note the hypoechoic abscess cavity (asterisk) surrounded by a well-defined slightly more hyperechoic border. The globe (G) is located at the left of the image.

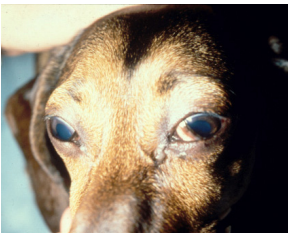


Figure 6. Bilateral exophthalmos and protrusion of the third eyelids are attributable to substantial inflammation of the temporalis, masseter, and medial pterygoid muscles in this 10-month-old male Miniature Dachshund with acute masticatory muscle myositis.



Figure 7. Bilateral enophthalmos is present in this 7-year-old spayed female Golden Retriever with chronic masticatory myositis. Note the severe atrophy of the masseter and temporalis muscles resulting in a prominent zygomatic arch. Mild entropion of both upper eyelids and trichiasis of the upper eyelashes secondary to enophthalmos is present.



Figure 8. Bilateral exophthalmos, upper eyelid retraction, 360-degree scleral show, and absence of protrusion of the third eyelid are evident in this 7-month-old female Golden Retriever with bilateral extraocular polymyositis.

Copyright © 2001

Waltham USA, Inc.

All rights including that of translation into other languages, reserved. Photomechanical reproduction (photocopy, microcopy) of this publication or parts thereof without written permission from Waltham USA, Inc. is prohibited.

The opinions expressed in these proceedings are those of the authors and not necessarily those of Waltham.

Additional copies can be obtained from Waltham USA, Inc. The proceedings may also be found online at the WALTHAM[®] web site at <http://www.walthamusa.com> or the VIN web site at <http://www.vin.com/OSUWaltham/2001/>.

Designed and published by Veterinary Information Network (VIN).