



REVIEW ARTICLE

A review of feline infectious peritonitis virus infection: 1963–2008

Niels C Pedersen DVM, PhD*

Department of Medicine and
Epidemiology and Center for
Companion Animal Health, School
of Veterinary Medicine, University
of California, Davis, CA 95616,
USA

Date accepted: 3 September 2008

© 2009 Published by Elsevier Ltd on behalf of ESFM and AAEP.

Historical

Feline infectious peritonitis (FIP) was first described as an 'important disorder of cats' by Holzworth in 1963¹ at the Angell Memorial Animal Hospital, Boston and a clinico-pathologic conference on this disorder was published in the following year.² The disease was thought to be infectious but no specific etiologic agent was identified at the time. Wolfe and Griesemer³ were the first to propose that FIP was caused by a virus. Zook et al⁴ observed virus particles in the tissues of experimentally infected cats, but were unable to characterize the agent. Ward⁵ recognized the close similarities of FIP virus (FIPV) in tissues to members of the family *Coronaviridae*. In 1972 Montali and Strandberg⁶ were the first to report that FIPV infection could be either granulomatous (dry, parenchymatous) or effusive (wet, non-parenchymatous). The close genetic relationship of FIPV to coronaviruses of dogs and swine was first reported by Pedersen et al in 1978.⁷ Fully virulent FIPV was first propagated in vitro in autochthonous macrophage cultures from experimentally infected cats⁸ and later in tissue culture.^{9,10} It was also replicated in the epithelium of intestinal ring cultures.¹¹ A strain of FIPV (FIPV-UCD1) was first propagated in continuously passaged *Felis catus*, whole fetus-4 (Fcwf-4) cells and shown to be virulent when inoculated into cats.¹² The Fcwf-4 cells were later found to be of

a macrophage type.¹³ The existence of two serotypes, feline coronavirus (FCoV)-like and canine coronavirus (CCV)-like, of feline coronaviruses was first reported in 1984.¹⁴

The sudden appearance of FIP in the late 1950's was documented by long-term and meticulous necropsy records at the Angell Memorial Animal Hospital, Boston.^{1,15} Therefore, its existence as a significant disease entity prior to this time is questionable. A reference to a cat with a disease resembling FIP was published a half century earlier (Jakob¹⁶ as quoted in de Groot and Horzinek¹⁷), but whether this was FIP is uncertain given the absence of reports of a similar condition in the intervening decades. There was a steady increase in the incidence of the disease in the 1960s onward, and it is currently one of the leading infectious causes of death among young cats from shelters and catteries. The reason for the sudden emergence of FIP is not known, but there are at least three possible explanations. First, coronaviruses may have speciated into cats within the last half century. It is noteworthy that FIP appeared within a decade of the initial descriptions of transmissible gastroenteritis (TGE) of pigs in North America.¹⁸ The causative virus of FIP is closely related to the TGE virus of pigs and CCV,⁷ although they are still genetically distinguishable.¹⁹ However, recombinants between these three viruses are known to occur.^{14,20–22} At least one strain of CCV can induce mild enteritis in cats and enhance a subsequent infection with FIPV, indicating a special closeness to feline coronaviruses.²³ Therefore, CCV may be a more likely parent of FECV in this scenario. Recombination events are favored by the ease with which transcription units (RNAs) can be gained or lost during the divergent evolution of coronaviruses.²⁴

*Corresponding author. Present address: Center for Companion Animal Health, Room 213, CCAH Building, School of Veterinary Medicine, University of California, Davis, CA 95616, USA. Tel: +1-530-752-7402; Fax: +1-752-7701. E-mail: ncpedersen@ucdavis.edu

Secondly, the FIP mutation may be selective to a variant FECV that appeared in the 1950s. This variant could also have arisen because of the intra- and inter-species mutability of coronaviruses in general and in this case, FCoV in particular. A third explanation may involve changes in how cats were viewed as pets and their husbandry in this modern era. There was a dramatic shift in the status, keeping, and breeding of cats as pets after World War II. The numbers of pet cats greatly increased, purebreeding and cattery rearing became increasingly popular, and more cats, and in particular kittens, found themselves in shelters. These large multiple cat indoor environments are known to favor feline enteric coronavirus (FECV) infection and FIP (reviewed by Pedersen et al 2008).²⁵ Interestingly, feline leukemia virus (FeLV) infection also became rampant among indoor multi-cat households during this period, and FeLV infection was a significant cofactor for FIP until it was pushed back into nature with testing, elimination/isolation, and eventual vaccination in the 1970s and 1980s.²⁶

Causative agent

FIPV is a virulence form (biotype) of the FECV.^{27–29} The generic name FCoV has been loosely applied to all serotypes and biotypes of feline coronaviruses. Using this nomenclature, FECV is technically an enteric biotype of FCoV, while FIPV is an FIP biotype. Unfortunately, the widespread use of the generic term FCoV has led to confusion when reviewing the world's literature, because it is often difficult, and sometimes impossible, to determine which virus biotype is being discussed or even studied. To avoid confusion, this review will attempt to decipher the various authors' meaning when the generic term FCoV has been used, and to use FECV to refer to the ubiquitous enteric biotype of FCoV present in most healthy cat populations and FIPV when referencing the virulent biotype that causes FIP in individual cats.

The FIPV is somewhat unique from other viruses, because it is infrequently spread from animal to animal in a horizontal manner, yet it is highly infectious when extracts of affected tissues or fluids are inoculated into naïve cats by a number of routes (see discussion on experimental infection). In this regard, FIPV resembles the infectious acute sarcoma-inducing retroviruses of cats, where the mutant form is found only in tumors, and is not horizontally transmitted in nature, but the parent FeLV is shed in various excretions and secretions and horizontally spread.³⁰ Therefore, FIPVs are strongly cell and tissue bound and shedding in feces or urine would be possible only under special circumstances, such as if lesions efface the renal collecting ducts or intestinal wall and are shed in urine or feces. The infectivity of urine has been reported at least once in the literature.³¹

The genomic structure of all feline coronaviruses is similar. Their genomes are incorporated into a single RNA strand made up of around 29,000 nucleotides.

There are 11 putative open reading frames (ORFs) or genes, including a non-structural replicase with two large ORFs; four structural ORFs encoding the spike, envelope, membrane and nucleocapsid proteins; and five accessory ORFs (3a–c) and 7a,b. The 7a gene is not essential for virulence, based on identification of field strains of both FECV and FIPV that lack a functional 7a gene.³² Likewise, small deletion mutations in the 7b gene were found in 8/32 isolates associated with both enteric and infection and FIP.³³ However, the functionality of the mutated 7b genes was not mentioned.

The FIPV, like FECV, also exists in two serotypes based on virus neutralizing antibodies, type I and type II.^{14,34} Serotype I virus has a distinctively feline spike protein, while the spike protein of type II serotypes is a recombinant between feline and canine enteric coronaviruses.³⁵ Type I FECVs/FIPVs predominate throughout the world,^{14,36,37} but type II strains make up more than 30% of isolates in certain countries such as Japan.³⁸ Type II strains appear to be more adaptable to tissue culture; however type I strains may be more likely to cause clinical FIP.³⁷

In addition to the two serotypes, FECVs and their FIPV biotypes exist in numerous strains defined by distinct single nucleotide polymorphisms (SNPs) and insertion/deletions (INDELS). Differences are small between isolates within the same group of cats, seldom more than 1–2%, but can be up to 20% between isolates from geographically distinct regions. Mutations are found in all genes to some extent or the other, but tend to be concentrated in the nine accessory and structural genes rather than in the two genes comprising the large replicase. Functional mutations in several of the accessory genes, including 3c and 7b, do not appear to prevent replication either *in vitro*³⁹ or *in vivo*.^{29,40} There is no evidence that certain strains of FECV are more likely to mutate to FIPVs, but this needs to be more thoroughly studied.

The mutation responsible for the FIPV biotype is consistently found in the 3c gene, which encodes a small protein of unknown function (NC Pedersen, UC Davis, 2009, manuscript submitted).²⁹ The mutations are usually SNPs causing premature stop codons or deletion mutations that negate or significantly truncate the 3c gene product. The specific deleterious mutation in ORF 3c can differ even between affected kittens in the same litter (NC Pedersen, UC Davis, 2009, manuscript submitted), again supporting internal mutation and auto-infection rather than cat-to-cat transmission as the primary route of exposure. Loss of 3c gene function does not prevent replication *in vivo* or *in vitro*, but is thought to drastically alter cell tropism by enhancing internalization and replication of FIPVs in macrophages.^{41,42} In contrast, the parent FECV is more tropic for mature apical epithelium of the bowel.²⁷ However, this may be simplistic because FECV infection does have a systemic as well as intestinal phase and may be present in monocytes and phagocyte rich organs during primary infection.⁴³

The question, however, is to what extent FECV replicates in these non-intestinal cells and organs.

The FECV → FIPV mutation is more likely to occur during primary infection and in kittens, because both conditions lead to a higher level of FECV replication and the latter to a decreased resistance to the mutation once it occurs.²⁵ The FIPV mutants occurred in 20% of primary FECV-infected cats in one study.²⁸ However, FECV infection is often recurrent and there is some evidence that FIP may also occur as a consequence of these recurrent bouts of virus replication. Addie et al⁴⁴ followed 56 cats deemed to have recurrent FECV infections based on decreasing and rising antibody titers; 3/56 animals subsequently developed FIP.

The 'internal mutation' theory of the FECV → FIPV conversion has been recently questioned by Dye and Siddell.⁴⁵ They compared the full length genomic sequence of viruses found in two different tissues of a cat with classical FIP. This study was based on earlier findings of Addie et al,⁴⁶ which showed that many cats with FIP shed a coronavirus (presumably FECV) in their feces. Their FIPV was from lesional tissues (liver), while their putative 'FECV' was obtained from a segment of jejunum. They found no differences in sequence between the two viruses and suggested that this called the internal mutation theory into question. However, the sequences from viral genomes present in the two tissues showed extensive mutations in the 3c–7b region, which occur in FIPVs but not in true FECVs. The jejunum is a known site for FECV replication during acute infection,²⁷ which is in the ileum, the colon and the rectum.⁴⁷ Furthermore, we have recently documented that a portion of coronaviruses isolated from feces of cats with FIPV are much more likely to resemble the FIPVs in the tissue, than the parent FECV. This means that only fecal coronaviruses that have an intact 3c gene can be designated as an FECV. Therefore, the two viruses being compared by Dye and Siddell⁴⁵ were identical FIPVs.

Several studies have implied that whether a cat develops FIP after FECV exposure is determined by how the host responds to the virus and not from differences in biotype.^{48–51} Another study suggested that FIP results from the systemic spread of FECV from the gut into blood monocytes.⁴³ However, there should be no doubt that FECV and FIPV are genetically distinct in a minor but crucial manner, and that this difference is essential for causing FIP. Furthermore, immunity to FECV infection does not confer immunity to FIPV infection and differences in immunity to the two viruses are qualitative and not merely quantitative. However, host and environmental factors admittedly play a role in whether or not FIP is clinically manifested.^{28,52,53}

Epizootiology

FIP is mainly a disease of domestic cats. It has also been recognized in the African lion, Mountain Lion, Leopard, Cheetah, Jaguar, Lynx, Serval, Caracal, European

Wild Cat, Sand Cat and Pallas Cat.^{54–63} An almost identical infectious peritonitis has been described in interferon-gamma deficient mice^{64–66} and in ferrets⁶⁷ infected with their respective species of coronavirus.

FIP occurs wherever FECV is found^{27,44,53,58,68} and is, therefore, worldwide and ubiquitous among virtually all cat populations. Thus, the epizootiology of FIP is closely linked to that of FECV. Shedding of FECV can be transient, recurrent, or chronic over periods of months or years.^{25,69,259} The FECV is present in virtually all catteries and shelters with more than six cats and is shed by 60% or more of pet cats from multi-cat households. One-third of older cats and 90% of kittens and juveniles presented to shelters in Sacramento, CA, USA were shedding FECV at the time of entry.⁷⁰ A significant proportion of these cats were from the feral population, so it is fair to say that FECV is enzootic among both indoor and outdoor cat populations. Similar findings have been reported for most, but not all, other countries. Bell et al^{71,72} found the seroprevalence of FECV to be 34% among pedigree cats in the Sydney area and non-existent in feral cats tested. They confirmed that the number of cats per household had a significant influence on the infection rate, and that certain breeds had a higher incidence of seropositivity than others.

Extensive studies have been undertaken on both natural^{27,73,74} and experimental FECV infections.^{25,27} The infection is spread by the fecal–oral route and viral shedding in feces occurs within a week of exposure.²⁵ This shedding occurs from the ileum, the colon and the rectum.⁴⁷ Shedding of FECV can be persistent for up to 18 months or more, be persistent for 4–6 months and intermittent for months thereafter, or cleared within 6–8 months (studied and reviewed by Pedersen et al 2008).²⁵ However, immunity in recovered cats is tenuous and reinfections resembling primary exposure often occur. The same strain tends to persist in all cats within a given cattery or region; however, an occasional cat in a group may be infected with more than one strain or a different strain.^{73,259} Virus shedding is somewhat associated with coronavirus antibody titer levels; groups of cats with indirect fluorescent antibody titers of ≥1:100 or much more likely to have coronavirus shedders than groups of cats with titers of ≤1:25.²⁵

Most deaths from FIP occur in cats 3–16 months of age and are uncommon after 5 years.^{15,53} In one study, FIP was the most common single cause of disease in cats younger than 2 years of age, while cancer was the most common single disorder in the 2–8 years age range.⁷⁵ The incidence of FIP in a veterinary medical teaching hospital from 1986–1995 was 1:200 among new feline visits, 1:300 among total cat accessions, and 1 of 100 accessions at diagnostic laboratories.⁷⁶ The incidence of FIP is significantly higher among kittens and younger cats originating from purebreed catteries and shelters. An average of 1–5% of young cattery or shelter cats in the US will die from FIP, with losses in catteries higher than from shelters. Enzootics with >10%

mortality were noted at least once in 5 years among young cats and kittens originating from four typical catteries that were studied.⁵³ Cave et al⁷⁷ studied the causes of death among 274 sheltered and privately owned pedigreed and non-pedigreed kittens from 1986–2000. Twenty-five percent of all kitten mortality was due to feline parvovirus (FPV). The main viral infections in 15–38 day-olds were feline herpesvirus and feline calicivirus. FIP caused the death of 17/203 kittens in the postweaning (35–112 days of age) period, with an incidence of 8.4%.

The FIP losses occur as enzootics or epizootics, with the former being more common. The FIP losses are sporadic, unpredictable and infrequent in the enzootic form; catteries with enzootic FIP may not have any deaths for years, followed by several cases in rapid succession. The disease may then disappear, only to reappear months or years later. Overall mortality from enzootic disease over a 5-year or longer period is usually 1–5%. However, epizootics of 3–49% have been observed in groups of kittens raised in one cattery over a 4-year period and similar explosive outbreaks have been seen in several other catteries.^{58,78} Epizootics of FIP seldom last for more than 6–12 months before returning to an enzootic state. Enzootic FIP is usually associated with persistence of the same or similar strains of enteric coronaviruses within a population, while epizootics are multifactorial and reflect increased population stresses, usually associated with overcrowding and high kitten production, the unintentional use of genetically predisposed breeding stock, possible bouts of horizontal transmission, or the introduction of a new strain of FECV.

Several risk factors for FIP have been identified in catteries.⁵³ In this study FIP was not significantly associated with particular catteries, mean cat number, mean age, gender, cattery median coronavirus antibody titer, husbandry and quarantine practices, caging and breeding practices, or prevalence of concurrent diseases. However, individual cat age, individual cat coronavirus titer, overall frequency of fecal coronavirus shedding, and the proportion of cats in the cattery that were chronic FECV shedders, were associated with increased risk of FIP. Deaths from FIP were more frequent in fall and winter, and on the basis of analysis of cattery records, the number of deaths varied yearly. Epizootics (>10% mortality rate) were reported at least once in 5 years among the four catteries studied. One of the most significant factors appeared to be genetic susceptibility, which accounts for up to 50% of the incidence.⁵² Multi-cat households that have not personally experienced FIP losses, but which relocated or sold cats that later develop FIP, were no more likely to experience FIP over a 6-year period than households that had experienced no prior FIP losses or catteries that had lost cats to FIP.⁷⁹ Thus, every cattery with enzootic FECV infection is at risk of losing cats from FIP if they breed enough kittens over a long enough time. The risk of developing FIP appears to decrease over periods of 3 years in groups of cats, indicating an increase in population resistance.⁷⁹

The incidence of FIP in shelters seems to be directly correlated with the numbers and density of young cats and the length of time that they are held before adoption; greater and longer being much worse (K Hurley, UC Davis, unpublished findings, 2008). Reports from the US and Europe indicate an increased risk for young cats, purebreds, and intact males and a decreased risk in spayed females.⁷⁶ A report of 42 confirmed FIP cases from Australia between 1990 and 2002 has shown FIP to be over-represented in certain pure breeds (Burmese, Australian Mist, British Shorthair and Cornish Rex) and under-represented in other breeds (domestic shorthair, Persian) and a more even distribution across the age spectrum.⁸⁰ The breed incidence of another veterinary teaching hospital was analyzed over a 16-year period and the breed, gender and reproductive status of affected cats were compared to the general cat population and to mixed breed cats evaluated during the same period.⁸¹ As with previous studies, sexually intact cats and purebred cats were significantly more likely to be diagnosed with FIP; males and young cats also had a higher prevalence of disease. Abyssinians, Bengals, Birmans, Himalayans, Ragdolls and Rexes had a significantly higher risk, whereas Burmese, Exotic Shorthairs, Manxes, Persians, Russian Blues and Siamese cats were at decreased risk. Such studies indicate that the incidence of FIP among breeds can vary greatly between countries and regions and FIP losses are probably more related to bloodlines within a breed than to breeds themselves.

Clinical features

FIP refers to the more common effusive (wet, non-parenchymatous) form of the disease; a transmissible inflammatory condition of the visceral serosa and omentum with exudation into the abdomen.³ A second form of the disease is characterized by granulomatous involvement of parenchymatous organs such as the kidneys, mesenteric lymph nodes, bowel wall, liver, central nervous system (CNS) and the eyes.^{6,15} Granulomatous FIP is called 'dry', parenchymatous, or non-effusive because there is no inflammatory exudation into body cavities.

The most common form of FIP is wet or effusive, although the proportion of cats with dry FIP appears to be rising over the last few decades. Cats rarely manifest both forms of the disease at the same time, and if they do, it is usually a transition stage from wet to dry or dry to wet. Under experimental conditions, cats that develop dry FIP often have a brief episode of effusive disease at the onset, while some cats with dry FIP may become more effusive in the terminal stages of their illness. However, these transitions are much less noticeable in nature.

The incubation period (time from infection to disease) of effusive FIP is 2–14 days under experimental conditions.^{12,82–84} The incubation period for experimentally induced dry FIP is several weeks longer.

However, the actual incubation period in natural infections is unknown, but there is evidence the infection may smolder in a subclinical state for weeks, months and even years before overt signs are noticed. In retrospect, the clinical onset of FIP may be preceded by a long history of vague ill health and stunted growth. Co-infections with other feline pathogens may lower resistance to FIPV or may complicate the disease picture (see preceding discussion).

The earliest signs of overt FIP, besides a failure to thrive in young cats, include a progressively worsening malaise, fluctuating fever, inappetence, and weight loss. Other signs of disease are superimposed on these basic disease signs, depending on the form and organ distribution of the inflammation (Table 1). Abdominal distension is the most common physical finding in wet FIP and ranks higher than cardiovascular disease, neoplasia, hepatic or renal disease as causes of ascites in cats⁸⁵ (Fig 1). The abdomen, besides being greatly enlarged, is often doughy feeling and painless on palpation, and a fluid wave is easily induced on percussion. Upon opening, the abdomen is found to contain up to a liter of a yellow-tinged, slight to moderately cloudy, mucinous fluid (Fig 2). Dyspnea can be a feature of cats with pleural involvement and thoracic effusions (Table 1). Clinical signs due to ocular and CNS involvement are seen in less than 9% of cat with the wet form of FIP (Table 1).

There are several uncommon features of effusive FIP that warrant mention. Intact males frequently develop scrotal enlargement due to extension of the peritonitis to the tunics surrounding the testes and edema (Fig 1). A syndrome of hepatic lipidosis and extreme skin fragility has been described in one cat with wet FIP.⁸⁶ In-utero FIPV infections have been observed in kittens born to queens that developed effusive FIP during pregnancy; pneumonia, pleuritis and hepatitis were the principal lesions in affected kittens.⁸⁷ Many cats with FIP have a generalized synovitis, due to immune complexing or the migration of infected macrophage/monocytes into the synovium. A cat with FIP may present, therefore, with signs of fever and

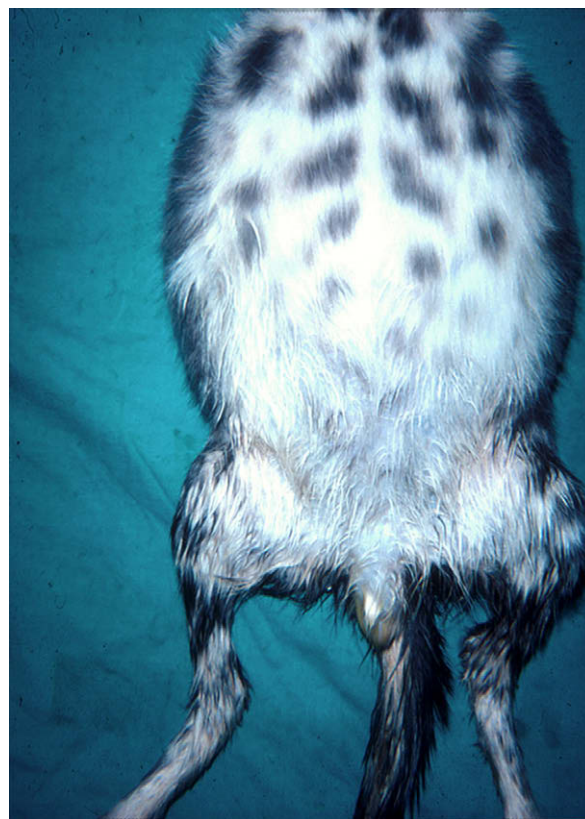

Fig 1. Grossly distended abdomen of a kitten with effusive FIP. Note the scrotal enlargement due to inflammation of the tunics.

lameness. This can be mistaken for another type of infection or an immune-mediated polyarthritis. However, the more classic signs of FIP usually develop soon after, making the cause of the lameness apparent.

Table 1. Variability in clinical signs of effusive (wet) FIP

Clinical signs referable to involvement of the:	% of affected cats
Peritoneal cavity	58.0
Peritoneal and pleural cavity	22.0
Pleural cavity	11.0
Peritoneal cavity and eyes	2.8
Peritoneal cavity and CNS	1.9
Peritoneal and pleural cavity, CNS	0.9
Peritoneal and pleural cavity, eyes	0.9
Pleural cavity, CNS and eyes	0.9
Peritoneal cavity, CNS, eyes	0.9

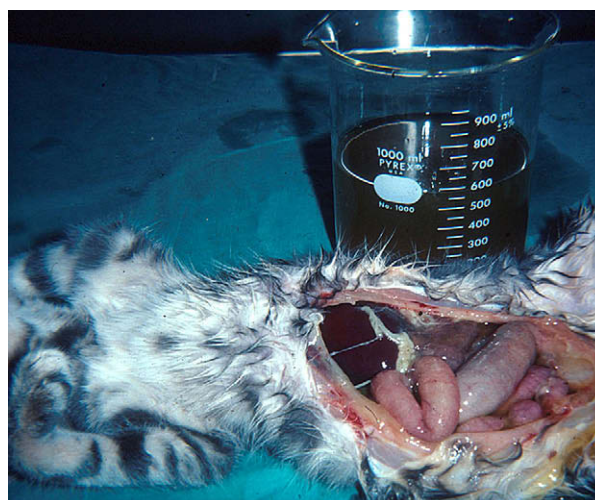

Fig 2. Over 600 ml of a yellow, mucinous effusion was removed from the abdomen at necropsy. Note fibrin tags on liver and spleen and ground glass appearance of the serosa.

Table 2. Variability in clinical signs of non-effusive (dry) FIP

Clinical signs referable to involvement of:	% of affected cats
Peritoneal cavity	32.0
CNS	23.0
Eyes	15.0
CNS and eyes	8.5
Peritoneal cavity and eyes	7.4
Peritoneal and pleural cavities	4.3
Peritoneal and pleural cavities, CNS	3.2
Peritoneal and pleural cavities, eyes	2.1
Peritoneal cavity, CNS, eyes	2.1
Pleural cavity	1.1
Pleural cavity, CNS, eyes	1.1

As the name 'dry FIP' implies, thoracic and abdominal effusions are either absent or too scant to be detected other than at necropsy. Involvement of the eyes and/or CNS predominates in 60% of the cats with dry FIP (Table 2). Signs referable to abdominal involvement are seen in 40% of animals, either with or without ocular and CNS disease (Table 2). The

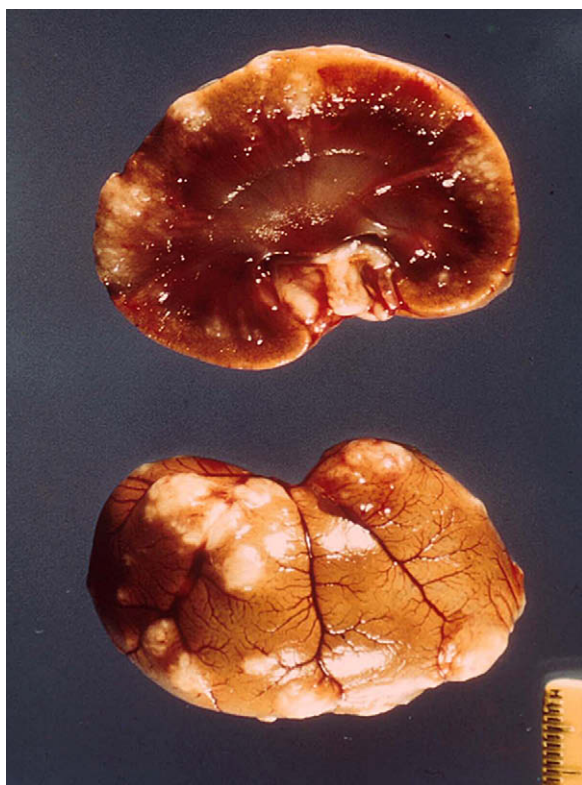

Fig 3. Cross section of a kidney from a cat with dry FIP. Numerous granulomatous lesions are seen on the capsule of the kidney and extending downward into the parenchyma.

abdominal lesions of dry FIP are much larger, fewer in number and less widespread than the lesions of wet FIP. Lesions of dry FIP tend to extend downward from the serosal or pleural surfaces into underlying parenchyma; hence the alternative name 'parenchymatous FIP'. Abdominal lesions are frequently found in the kidneys (Fig 3) and mesenteric lymph nodes (Figs 4 and 5), and somewhat less frequently in the liver and hepatic lymph nodes (Fig 5). Involvement of the wall of the caecum and colon with associated caeco-colic lymphadenopathy is a specific form of dry FIP (Fig 6) associated with signs typical of an ulcerative colitis (ie, soft, blood and mucus laden stools).^{88,89} Abdominal lesions are often evident on palpation and sometimes associated with local pain. About 10% of cats with dry FIP will have thoracic involvement, but chest lesions are usually localized and only one part of a more systemic infection. Small granulomas may involve the pleura and underlying lung parenchyma (Fig 7). Involvement of the pericardium has been described, and can lead to fluid distention of the pericardial sac, cardiac tamponade and heart failure.⁹⁰

CNS involvement is frequent in cats with dry FIP (Table 2). Over one-half of cats with inflammatory disease of the CNS have FIP, as well as one sixth of the total number of cats showing CNS signs from any cause.⁹¹ FIP is also the most common disease of the spinal cord in cats less than 2 years of age and is one of the three leading causes, along with lymphosarcoma and vertebral neoplasia, of spinal disease among cats of all ages.⁷⁵ Most cats with CNS FIP are less than 2 years of age and often originate from large multiple cat households.⁹²

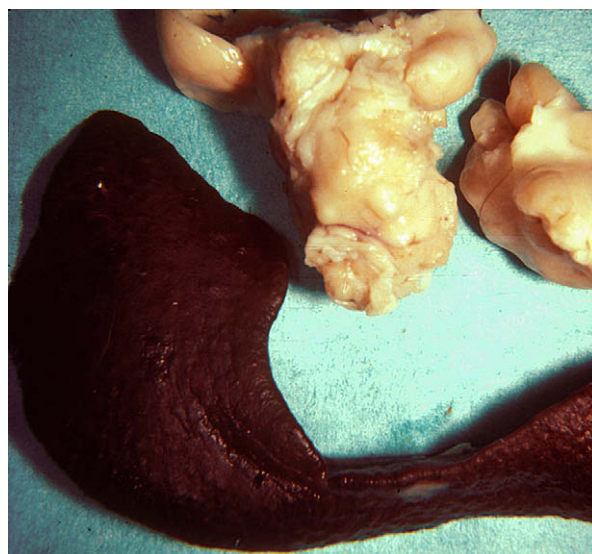


Fig 4. Enlarged mesenteric lymph node in a cat with the dry form of FIP. Note the residual fibrinous plaque on the spleen. Such residual lesions support the concept that many cases of dry FIP began as a brief bout of wet FIP.

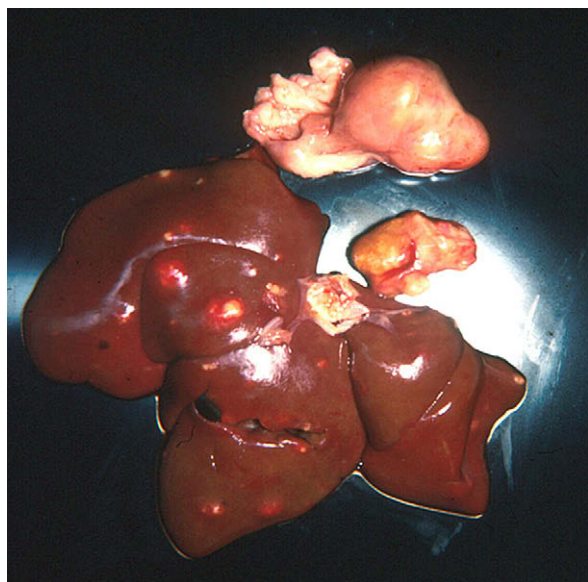


Fig 5. Mesenteric and hepatic lymph nodes and liver from a cat with non-effusive FIP. The lymph nodes are enlarged and involved with granulomatous adenitis. The liver capsule contains raised, whitish foci 0.5–1 cm in diameter, extending into the underlying parenchyma.

CNS involvement in cats with dry FIP is varied in its clinical expression, depending on what other organs are involved (Table 2), its exact localization in the nervous system, and severity. Signs referable to spinal cord involvement, such as posterior paresis, incoordination, hyperesthesia, seizures and palsy of the brachial, trigeminal, facial and sciatic nerves, have all been reported.^{15,75,93–98} Hydrocephalus, secondary to disease of the choroid and ependyma, has also been documented^{92,99–101} and can lead to dementia, personality changes (aggression, rage, hiding/withdrawal, etc) or convulsive disorders. Cerebellar–vestibular

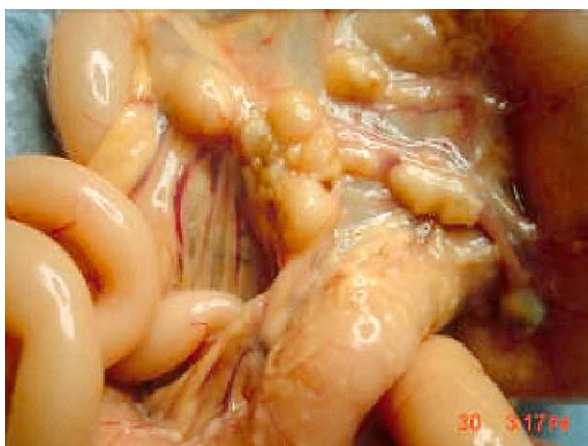


Fig 6. Gross appearance of the caecum, colon and cecocolic lymph nodes of a cat with the intestinal form of dry FIP.

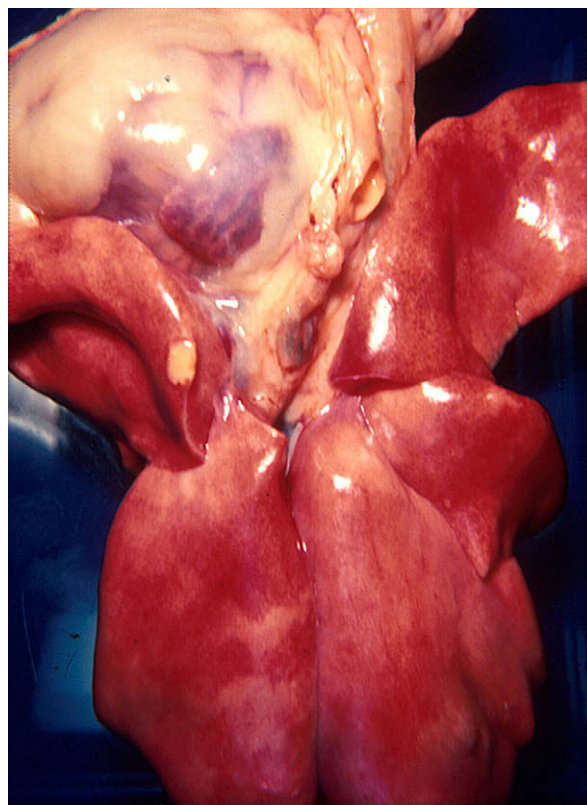


Fig 7. Lungs and heart of cat shown in Fig 5. A solitary pleural granuloma is noted along the edge of a cranial lung lobe.

signs, such as nystagmus, head tilt or circling, have also been caused by FIP.

Ocular involvement, like CNS disease, is much more likely to occur in cats with dry than wet FIP (Tables 1 and 2). Uveitis and chorioretinitis are the predominant ocular manifestations of dry FIP^{96,102–106} (Figs 8 and 9). FIP is also the most frequent cause of uveitis/chorioretinitis in cats, with less common causes being FeLV-associated lymphosarcoma; trauma; toxoplasmosis; and lens-induced uveitis.^{107,108} Ocular disease in dry FIP occurs solely or in association with lesions in the CNS or peritoneal cavity (Table 2). A change in the coloration of the iris is a frequent early sign of ocular FIP (Fig 8). Keratic precipitates on the caudal aspect of the cornea are characteristic of FIP and are due to accumulations of fibrin, macrophages, and other inflammatory cells (Fig 9). Focal lesions akin to the granulomas of parenchymatous organs may be apparent in the iris and distort the shape of the pupil (Figs 8 and 9).

There are several uncommon, but interesting, manifestations of dry FIP. Granulomatous involvement of the peripheral tissues resulted in priapism in a castrated cat.¹⁰⁹ Chronic fibrinous and necrotizing orchitis may cause the scrotum and testicles to appear enlarged^{110,111} and scrotal enlargement may be one of the primary presenting complaints. Miscellaneous sites for lesions in non-effusive FIP include the nasal

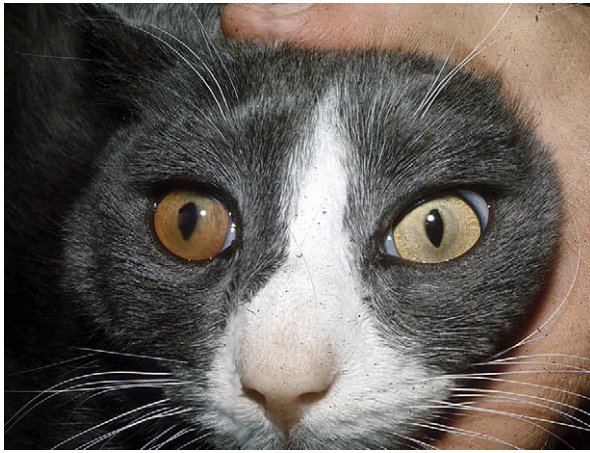


Fig 8. Uveitis of the right eye in a cat with the dry form of FIP. The color of the iris has changed, the anterior chamber is somewhat hazy, and there is a pigmented lesion in the center of the cornea (a keratic precipitate). Note the irregularity in the shape of the right pupil compared to the normal left pupil.

passages, tongue and distal small intestine. Syringomyelia has been caused by involvement of the fourth ventricle in one cat.¹¹² Cutaneous lesions of a granulomatous type have been reported in a feline immunodeficiency virus (FIV) infected cat with FIP; the lesions were thought to be due to a coronavirus

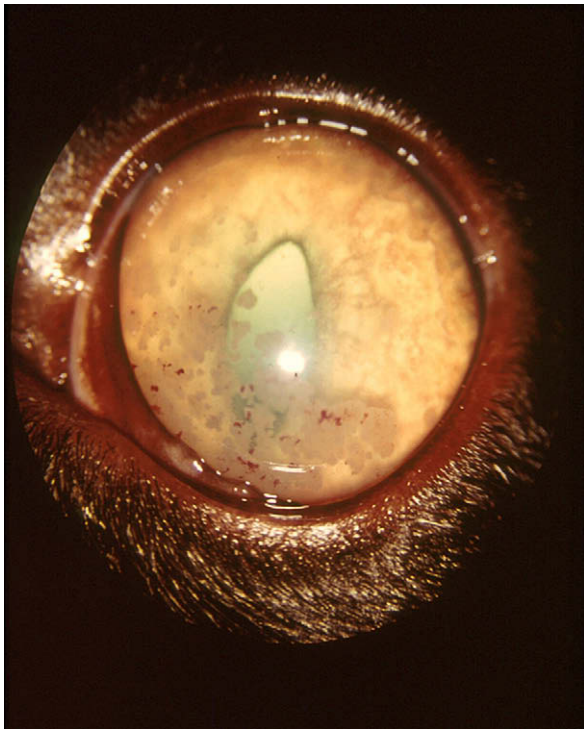


Fig 9. Keratic precipitates on the inner cornea of a cat with dry FIP. Note the reversed D-shape of pupil due to infiltration of the iris.

induced vasculitis.¹¹³ Toxic epidermal necrolysis has also been observed in a cat with dry FIP (NC Pedersen, UC Davis, unpublished observation, 2008). Non-puritic, slightly raised intradermal papules over the neck and chest walls were observed in the terminal stages of a cat that had non-effusive, progressing to effusive, FIP.¹¹⁴ The FIPV was identified in skin lesions by immunohistochemistry.

The lesions of dry FIP have also been mistaken for cancer, in particular lymphoma.^{94,115} One FeLV negative cat with FIP subsequently developed a myeloproliferative disease.¹¹⁶ Monoclonal gammopathies have been observed in four cats with FIP¹¹⁷ and a fifth cat with FIP was observed to convert from a polyclonal to monoclonal-gammopathy (Hurvitz, 1982 as quoted in Pedersen, 1987).¹¹⁹

FIP has many interesting interactions with other infectious agents. These agents may affect immunity to FIPV, such as FeLV infection. Alternatively, FIPV may induce an immunosuppression that encourages opportunistic type pathogens. Concurrent FeLV infection was seen in one-third to one-half of all FIP cases that were tested in the 1970s and 1980s.^{15,120} Infection with FeLV seems to have a specific interfering effect on the ongoing immunity to FIPV. Cats that failed to develop FIP after experimental infection developed FIP within 6–16 weeks after becoming FeLV viremic, indicating that many FIP recovered cats maintain residual infections.¹¹⁹ Mimicking the situation in the field, FIP also appears after natural exposure to both viruses.^{119,121} With the virtual elimination of FeLV from pet cat populations in westernized countries, this relationship has become much less common. Affected kittens with subclinical or clinical FIP are more susceptible to upper respiratory infections caused by mycoplasma, chlamydophila or herpesvirus, indicating that their resistance is not normal. It is also known that cats with advanced FIV infection are more susceptible to FIP when exposed to FECV.²⁸ Systemic toxoplasmosis, a relatively rare clinical infection of cats, has been described in two cats with FIP. One report was from 1966¹²² and a second report from 1995.¹²³ The occurrence of systemic toxoplasmosis in these two cats was probably associated with reactivation of encysted organisms left from a much earlier self-limiting infection. FIP is frequently associated with a lymphopenia, which is a non-specific finding indicative of immunosuppression. We have also noticed an increase in bacterial infections in cats with FIP, some manifested as terminal sepsis or more chronic local infections of internal organs (NC Pedersen and P Pesavento, UC Davis, unpublished observations, 2008). One young cat had a chronic bacterial infection of the reproductive tract that was manifested early as a purulent vaginal discharge and terminally as a suppurative infection of the ovary and fallopian tube, while a second cat had a secondary bacterial pneumonia. The stresses of pregnancy and parturition, surgical procedures such as spaying, neutering and declawing have also increased the incidence of

FIP in young cats, suggesting that stresses occurring at a time when the young cats are fighting an FIPV infection may tip the balance against the host.¹⁵

Pathogenesis

The FIPV enters target macrophage/monocytes by first binding to the cell surface and then being internalized by a clathrin and caveolae independent and dynamin dependent endocytosis.¹²⁴ Dewerchin and coworkers¹²⁵ added upon these findings and suggested that viral antigen-antibody complexes in FIP were not internalized through any of the previously described pathways. The internalization process was independent from phosphatases and tyrosine kinases but did depend on serine/threonine kinases. Once internalized, viral antigen-antibody complexes pass through the early endosomes and accumulate in the late endosomes. The complexes left the late endosomes within 30–60 min but were not degraded in the lysosomes.

Binding involves specific attachment sites on the spike protein and corresponding cell-surface receptors. The cellular receptor appears to be aminopeptidase-N, which was first identified as the receptor for TGE coronavirus of swine.¹²⁶ Aminopeptidase-N is a cell-surface metalloprotease on intestinal, lung and kidney epithelial cells. However, this interaction may be host species specific, because non-permissive cell lines genetically engineered to express porcine aminopeptidase-N become permissive to transmissible gastroenteritis virus (TGEV) but not to feline and canine coronaviruses.¹²⁶ The species specificity of the aminopeptidase-N receptor has also been shown by testing intraspecies chimeras of the protein.¹²⁷ Determinants on aminopeptidase-N responsible for binding of porcine, feline, and canine aminopeptidase-N to their respective host coronaviruses are found on its C-terminus.¹²⁸ Hohdatsu et al¹²⁹ noted differences in receptors for serotype I and II FIPVs using the blocking effect of specific mouse monoclonal antibodies. Their findings suggested that feline aminopeptidase-N is a receptor for type I FIPV but not necessarily type II FIPV. Interestingly, although neither porcine nor human aminopeptidase-N will act as a receptor for FIPV, a chimera of both is able to act as a receptor for FIPV.¹³⁰ All of these findings suggest that subtle differences in certain regions of aminopeptidase-N can radically change species and even serotype tropisms.

The acquisition of macrophage tropism appears to be an essential step in the evolution/transformation of an FECV to an FIPV and from a largely non-pathogenic and localized enterocyte pathogen to a highly virulent and systemic monocyte/macrophage pathogen. The relationship between virulence and macrophage/monocyte tropism has been firmly established in the literature. Attachment and internalization of FIPV by monocytes by endocytosis has been compared for two FIPV strains; FIPV-79-1146 being internalized much more efficiently than FIPV-Black.¹³¹ Strains of

FIPV such as WSU-79-1146 are more macrophage tropic than tissue culture-adapted and non-virulent strains such as WSU-79-1683. The former virus is assumed to be a prototypic FIPV, while the latter is assumed to be the prototype of an FECV.⁴⁰ However, the assignment of these isolates as prototypic may have been premature. Both are serotype II viruses, unlike most field strains of FECVs and FIPVs; both are tissue culture-adapted to non-macrophage cell lines; and FIPV-WSU-79-1146, unlike a number of serotype I FIPVs, is exceptionally virulent by every common route of infection (Table 3). The same doubts apply to WSU-79-1683 as a prototypic FECV. It lacks most of the 7b gene, which is present in non-tissue culture-adapted strains of FECV¹³² and all other attempts to adapt additional field strains of FECV to tissue culture have so far failed. We have also noted that WSU-79-1683 has a deleterious mutation in its 3c gene, indicating that it may have originated from an FIPV (NC Pedersen, UC Davis, personal observation, 2008). However, WSU-79-1683 does behave as an enteric biotype, when compared to FIPV-WSU-79-1146, in its dependence on cathepsin B and cathepsin L activity and low pH for entry into host cells.¹³³ It also causes an inapparent to mild enteritis when infected into laboratory kittens, targets appropriate tissues, and does not cause FIP.⁴⁰ Nevertheless, without more bonified tissue culture-adapted FECV strains, grown on appropriate host cells, comparisons of macrophage versus enterocyte tropisms of FECVs and FIPVs in vitro using these two FCoV biotypes, should be interpreted with some caution. Studies with FECVs have been undertaken in nature, but they have dealt more with systemic spread than intestinal tropism. For instance, FECVs may be detected in the blood during the course of natural infection,⁴³ but at much lower levels than seen

Table 3. Virulence (lowest to highest) of several tissue culture-adapted strains of FIPV

FIPV strain	Route infection	Mortality
FIPV-UCD2	IN (intranasal)	0/5
	IP (intraperitoneal)	0/5
FIPV-UCD3	PO (by mouth)	0/4
	IP	2/5
FIPV-UCD4	PO	0/4
	IP	3/8
FIPV-UCD1	PO	3/15
	IT	7/10
	IP	4/4
Wellcome	PO	3/4
	IP	4/4
FIPV-TN406 (Black)	PO	4/5
FIPV-79-1146 (-Nor15)	PO	25/27
	IP	7/7

with FIPVs.¹³⁴ Therefore, the affinity of the enteric biotype for the intestinal epithelium (Fig 10) and the FIP biotype for macrophages may be more quantitative than qualitative.

The genetic basis for differences in macrophage tropism between FECVs and FIPVs is not fully understood. It would be logical to assume that the differences are due to characteristic functional mutations in the 3c gene. However, some research suggests that the acquisition of macrophage tropism by FIPVs is determined by mutations in the spike protein.⁴² Unfortunately, this study also compared WSU-79-1683 and WSU-79-1146, which do not appear to be typical for either of their respective biotypes. Mutant viruses of the FIPV phenotype have been detected in as high as 20% of primary FECV infections,²⁸ indicating that macrophage tropic mutants occur with great frequency. However, only a fraction of mutants may actually produce a progressive disease.^{28,52} These abortive infections are thought to be associated with a strong and rapid cellular immune response and are probably contained within the mesenteric lymph nodes. In the unfortunate cats, mutant viruses are allowed to proliferate unchecked within macrophages and are carried by these cells to specific sites in the body.¹³⁵ Many of these tissues and organs appear to be fed by the cranial mesenteric artery and are rich in phagocytic cells. Targets are the mesenteric lymph nodes, serosal surfaces of the gut, and to a lesser extent the pleura, and the omentum. Some virus also appears to reach the meninges (especially on the posterior-ventral surfaces of the brain), the ependyma

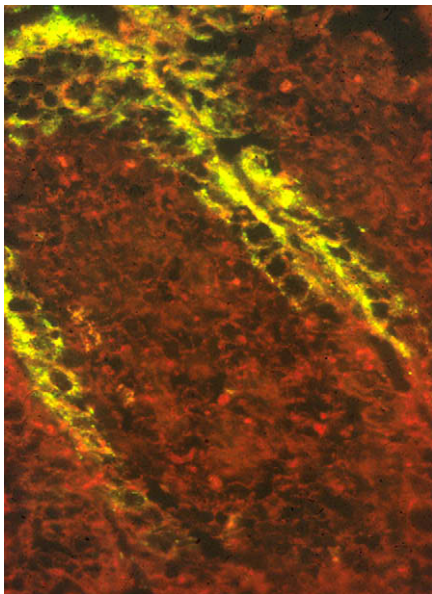


Fig 10. Immunofluorescent antibody staining for feline coronavirus antigens on a section of small intestine from a cat experimentally infected with FIPV. Virus is concentrated in the mature apical epithelium at the tips of the intestinal villi.

surrounding the ventricles, the dura mater of the spinal cord, and the uveal tract and retina of the eyes.

The issue of whether different variants of FIPV can exist in the same cat was raised by Battilani et al,¹³⁶ who analyzed quasispecies composition and phylogenetic relationships of coronaviruses in cats with naturally acquired FIP using single-strand conformational polymorphisms in the nucleocapsid and 7b genes. They found a high degree of heterogeneity, especially in the nucleocapsid gene, which correlated directly with the seriousness of the clinical disease. Sequences also varied according to geographical origin. The existence of quasispecies in cats with FIP has recently been confirmed in the author's laboratory. Two of four sibling cats that died of FIP were found to have two distinct variants in their tissues, and two or more variants in their feces, at the same time (NC Pedersen and H-W Liu, UC Davis, personal observation, 2008). A recent published immunohistochemical study on brain lesions from 15 cats with the dry form of FIP used two different monoclonal antibodies directed against unrelated epitopes of CCV to search for variants.¹³⁷ These authors also used a myeloid-histiocytic marker, MAC387, to identify infected macrophages. Double immunostaining demonstrated macrophages that were positive for either the CCV-monoclonal antibody alone, or for both the CCV- and FIPV-monoclonal antibodies. The conclusion was that there were two cohorts of phagocytes, both containing virus with the CCV-epitope, but differing by the presence or absence of the FIPV epitope. Unfortunately, the strength of reactivity of the two monoclonal antibodies differed and the authors did not consider that various macrophages contained different amounts of antigen, giving the impression that there was differential staining. Given the origin of FIPVs, it is not surprising that a similar phenomenon was observed in cats infected naturally and experimentally with FECVs.¹³⁸ Most cats shed FECV in feces throughout the experiment without disease signs. Sequences from the nucleocapsid and 7b genes were amplified by reverse transcriptase polymerase chain reaction (RT-PCR) from the cerebral cortex, dura mater, pancreas, lungs, third eyelid, and the heart muscle in four cats. Viruses differed between organs in whether or not they expressed the 7b gene and in their nucleocapsid gene sequences.

Virus replication in macrophages appears to be very slow during the first 2 weeks or so. A dramatic increase in the levels of macrophage infiltration, macrophage infection, virus replication, and viral spread occurs around 10–21 days after primary infection in experimental infections, coincidental with the appearance of virus specific antibodies.^{139,140} Recovery, when it occurs, probably takes place sometime during this initial quiescent period. Antibodies are virus neutralizing in vitro, but appear to have a disease facilitating effect in vivo. The failure of the antibody response to neutralize or prevent virus spread in vivo can be explained in at least two ways. First, antibody binding

to virus may block aminopeptidase-N receptors and prevent virus-to-cell attachment, but enhance virus uptake by macrophages through their complement binding (Fc) receptors. This antibody-mediated enhancement is specific for feline antibodies and feline macrophages, and may involve antibodies to both virus spike and membrane proteins.¹⁴¹ Second, viral antigens may not be arrayed on the surface of infected macrophages, thus limiting virus spread to intimate cell-to-cell contact.¹⁴²

The hallmark of the antibody phase of the infection is a rapidly spreading serosal/omental centered inflammation associated with expanding cycles of macrophage infection, virus replication, virus release from dying infected macrophages, and yet more virus bound by yet more macrophages. This reaction is centered on small venules and the result is a lesion called a pyogranuloma. Pyogranulomas form around small venules in target tissues and are surrounded by an influx of protein-rich edema fluid, and a sprinkling of lymphocytes, neutrophils and plasma cells. This reaction has been likened to Arthus-type hypersensitivity.^{13,143,144} Cytokines and other inflammatory mediators released by macrophages and polymorphonuclear leukocytes undoubtedly add to the character and intensity of the lesions.

Complement activation and vascular damage results in a disseminated intravascular coagulopathy (DIC),¹⁴⁵ which is not usually clinically appreciated. Cats, by their nature, are much less likely to develop overt hemorrhages when in DIC, but DIC may contribute to the mucinous nature of the FIP exudate. The yellowish or bluish tinged fluid, serum, and urine, which are often found in cats with FIP, are also due to microhemorrhage and red cell damage resulting from vasculitis, complement and clotting factor activation, and DIC. Red blood cells that leak into the tissues, or manage to make it to the spleen in a damaged state, are destroyed by phagocytes. An attempt is made to recycle hemoglobin by breaking it down to biliverdin and bilirubin. The carrier proteins of both biliverdin and bilirubin are rapidly saturated in cats, allowing them to build up to detectable levels in the exudate, serum, urine and tissues.

The occurrence of two forms of FIP, effusive (wet, non-parenchymatous) and non-effusive (dry, parenchymatous), has long been intriguing. Observations with experimentally and naturally infected cats show that dry FIP is often preceded by a brief episode of wet FIP. The lesions of dry FIP are therefore remnants of an initial surface orientated infection. Dry FIP may also become effusive in the terminal stages of disease when the immune system collapses. The dry form of FIP is presumed to result from a state of partial protective immunity. Protective immunity to FIPV is largely cell mediated and involves a change in the way infected macrophages respond to virus and vice versa. If infected macrophages receive proper signals from the host, they gain the capacity to destroy virus rather than to act as virus incubators and

disseminators. The host also comes to view infected macrophages as foreign and will attempt to destroy them as well. If the cellular immunity develops early in the course of infection and has sufficient strength, clinical signs of disease will not occur and virus replication will be checked. Some virus may persist in a subclinical or latent state, most likely within macrophages in organs such as the mesenteric lymph nodes, for months or even years. If humoral immunity occurs, but cellular immunity fails to develop, the resulting disease is effusive or wet. However, an intermediate stage of immunity can also occur, with strong humoral immunity and weak cellular immunity. Virus is contained to a much greater extent than in the effusive form of the disease, but is not fully eliminated. A tug of war between virus replication and virus destruction follows, resulting in the non-effusive or dry form of FIP. This form of the disease is characterized by more classic granulomas. Unlike the pyogranuloma, which is filled with virus laden macrophages and a few scattered neutrophils and lymphocytes, the granuloma contains small foci of macrophages in the center, many of which contain no or small amounts of viral antigen, surrounded by broad bands of lymphocytes and plasma cells. Granulomatous lesions of dry FIP are less common and much less widespread than pyogranulomas of wet FIP, and tend to extend down from the surfaces of organs into the underlying parenchyma. This surface orientation of granulomas is consistent with their origin as pyogranulomas. The organ distribution of the lesions of dry FIP can also be explained by a state of partial or weak immunity. During the initial stage of FIPV infection, virus reaches the brain and eyes via infected monocytes, but immunity has difficulty penetrating these areas due to the blood-brain barrier. If protective immunity is strong, virus and virus-infected cells will be easily cleared from organs on both sides of the blood-brain barrier. However, if protective immunity is weak, it will be more effective in handling virus and virus-infected cells in the core of the body than it will be in the eyes and brains. Therefore, lesions in the brain and eye will be more likely to persist than lesions in the abdomen or other sites, thus providing an explanation as to why ocular and CNS lesions predominate in the dry form of FIP.

Hematologic, clinicopathologic and imaging features

The diagnosis of FIP should be relatively simple, given its affinity for younger cats, its strong tendency to involve catteries and shelters, the typical physical and historical findings, and numerous characteristic laboratory abnormalities. Nonetheless, it somehow remains one of the most difficult of diagnoses for many veterinarians. The truth is that veterinarians have little trouble in placing FIP high, or at the top, of their diagnostic list, but have great difficulty, and even reluctance, in confirming their diagnosis. However, it is

not only the veterinarian that has difficulties, but the owners as well are reluctant to give up without a definitive diagnosis. It must be remembered that a diagnosis can be based on cumulative odds rather than a single, simple, definitive test result. A young cat from a cattery or shelter with chronic uveitis and/or neurologic signs, high serum proteins, hyperglobulinemia and hypoalbuminemia, fluctuating antibiotic unresponsive fever, leukocytosis with a lymphopenia, and an anemia of chronic disease can have no other disease than dry FIP based on odds alone. Likewise, the same cat with similar history and laboratory findings, but with a yellow-tinged, mucinous, inflammatory ascites instead of uveitis or neurologic signs is highly unlikely to have any other disease than wet FIP. Results from a test that is incorrectly touted as being definitive or highly indicative of FIP will only confuse the issue and induce doubt when the diagnosis should not have been in doubt. Ultimately, FIP must be diagnosed by applying a workable knowledge of the disease with sensible weighing of signalment, history, clinical signs, clinicopathologic findings, serology and ante- or post-mortem examination of affected tissues by histopathology and immunohistochemistry.

Hemograms of cats with FIP often demonstrate several abnormalities, which tend to be similar regardless of the form of disease. A low-grade to moderately non-responsive anemia with hypoalbuminemia is typical of chronic disease. Other common hematologic changes include a leukocytosis with an absolute lymphopenia and neutrophilia, and hyperproteinemia.^{15,146–148} Serum total protein elevations are associated with increased levels of globulin and decreased levels of albumin. Cats with virus positive lymph nodes at necropsy were purportedly more likely to have globulin elevations.¹⁴⁷

Hypergammaglobulinemia is not directly related to FCoV antibody titers,¹⁴⁶ suggesting that non-specific antibody globulins and/or complement factors are important contributors to the globulin elevation. An albumin globulin ratio <0.6 is considered diagnostic for an inflammatory process, and most commonly FIP.¹⁴⁹ The most consistent changes shown by serum protein electrophoresis were increases in α 2- and γ -globulins.^{15,146,148} Haptoglobin makes up most of the increase in α 2-globulins.¹⁵⁰

Abdominal and pleural effusions of FIP have characteristics that are as definitive as any other single test. Almost one-half of all effusions in cats are due to FIP¹⁴⁹; therefore, the odds of FIP are 50:50 by the presence of an effusion alone. If the effusion have the features of FIP the odds are even greater; if the cat is younger the odds are greater still, if the cat is from a shelter or cattery, the odds go up even more, etc. FIP effusions are usually a light to dark yellow, and occasionally green-tinged, due to elevated levels of bilirubin or biliverdin, respectively. The fluid is mucinous in character and when a drop on a slide is touched with a needle tip and then pulled away, a string will often form. The fluid ranges from

somewhat clear to cloudy and often contains visible fibrin tags. The protein content of the effusions ranges from 3.9 to 9.8 mg/ μ l with the globulins comprising 50–82% of the total.¹⁴⁸ Cell counts can range from 1600 to 25,000 per μ l. Macrophages, non-toxic neutrophils and lymphocytes predominate. Fluid effusions, particularly from the pleural cavity, may be tinged with red cells. Effusions will often form partial clots when allowed to sit in an anticoagulant free tube. The electrophoretic pattern of the effusions will be similar to that of the corresponding serum.¹⁴⁶ Antibody titers higher than those of the corresponding serum have often been detected in the effusions,¹⁴⁶ but like comparative antibody titers in serum and cerebrospinal fluid (CSF),^{92,151} the significance of this finding has not been determined. A definitive diagnosis can be made by direct immunohistochemical examination of cells in the fluid for viral antigens.^{146,152} Immunofluorescence is several times more sensitive than immunoperoxidase. Real-time RT-PCR analysis of cells from FIP effusions will demonstrate high levels of viral RNA.

Hyperbilirubinemia, and less commonly hyperbiliverdinemia, frequently without jaundice, are common in cats with FIP, especially the effusive form. In fact, FIP is the most common cause of an icteric serum or plasma in cats under 3 years of age. The urine is also yellow-tinged due to a hyperbilirubinuria. A greenish hue to the urine and serum is less common and due to high levels of biliverdin. The increased level of bilirubin or biliverdin in the blood is usually not due to liver involvement per se, but rather to microhemorrhage into tissues and extravascular destruction of red blood cells by phagocytic cells, as part of the vasculitis and DIC. Heme from destroyed red cells is then recycled as biliverdin and finally bilirubin. Cats are deficient in carrier systems to remove these hemoglobin breakdown products from the blood, hence their tendency to accumulate in effusions, lesions, or serum.

Aqueous humor and CSF in cats with ocular or CNS disease also show similar, but more variable, increases in proteins and leukocytes. Typical CSF findings in cats with FIP include a protein concentration of greater than 200 mg/dl and a white cell count of over 100 cells/ μ l, consisting predominantly of neutrophils.¹⁵³ In contrast, the CSF of cats with other viral disease usually has a protein concentration of less than 100 mg/dl and a total white cell count of less than 50 cells/ μ l. Singh et al¹⁵⁴ defined an inflammatory CSF as having a total nucleated cell count greater than 5 cells/ μ l, or one in which the total count was normal but the differential count was abnormal. Gender, degree of CSF inflammation, neuroanatomical location and systemic signs provided were not helpful in determining whether the inflammation was due to FIP or other diseases such as cryptococcus, lymphoma or trauma. Synovial fluid from cats with effusive FIP is frequently inflammatory in character.

Many serum antibody tests have been used for the diagnosis of FIP, including indirect immunofluorescent antibody (IFA), virus neutralization, and enzyme-linked immunosorbent assay (ELISA).^{155–157} Some feel that ELISA is the most sensitive procedure,¹⁵⁷ but this author feels that most antibody tests are equivalent if done properly. The most common test is an IFA assay using TGE virus³⁷ or FIPV¹⁵⁶ infected swine or cat cells as a substrate. Titers are usually read in distinct multiples of serum dilutions (1:5, 1:25, 1:100, 1:400, 1:1600, 1:6400, ...). They were originally reported as being helpful in diagnosing cats that had FIP or were suffering from other illnesses.¹⁵⁶ Unfortunately, coronavirus antibodies do not differentiate between cats infected with FECV and FIPV, and although very high titers ($\geq 1:1600$) are highly suggestive of FIP and negative titers tend to rule out FIP,^{149,156} the overlap in titers between healthy coronavirus-exposed and diseased cats is so great that it has little definitive diagnostic value in individual animals.^{58,68,146,148} Titers appear to rise progressively in many cats as they go from a subclinical to clinical stage of disease.¹¹⁹ However, progressive monitoring of titers is rarely done and titers are usually measured when disease signs appear and titers levels have already plateaued. Moreover, titers may also fall dramatically at the end, especially in cats with fulminating effusive FIP.

The sensitivity and specificity of so-called FIP serology has been repeatedly questioned. Hematology, antibody titers and serum protein electrophoresis from 48 cats (34 effusive and 14 non-effusive forms) affected with FIP were studied and compared with those of 20 healthy cats.¹⁴⁸ In the effusive form, antibody titers and protein electrophoresis in the effusions were analyzed. Seropositive animals (antibody titer $> 1:100$) were present among both the FIP infected (73%) and healthy cats (70%). Sparkes et al¹⁴⁸ also compared serologic data from 65 cats in which FIP was considered as a differential diagnosis, but ended up having another disease. They found that the presence of multiple abnormalities compatible with FIP increased the specificity (ie, decreased false positives), but decreased the sensitivity of the diagnosis (ie, increased false negatives). However, there is no doubt that cats with very low or negative ($\leq 1:25$) FCoV antibody titers are less likely to have FIP, while cats with very high titers ($\geq 1:1600$) are more likely. Given these limitations, this author recommends that FIP serologic tests only be used as an aid in ruling in or out the possibility of FIP. The diagnosis of FIP should never be made on antibody titers alone, a recommendation made by others.^{72,158}

There have been many attempts to improve the specificity and sensitivity of antibody based tests for FIP. One commercial test measures antibody titers to the 7b protein of FCoV based on the presumption that a prototypic FECV (WSU-79-1683) lacks a 7b protein, while a prototypic FIPV (WSU-79-1146) has an intact 7b protein. In theory, cats with FIP should have

antibodies to the 7b protein, while cats exposed to the common FECV would not have such antibodies. Unfortunately, the lack of 7b protein in WSU-79-1683 is an artifact of that specific isolate and field strains of FECV have an intact 7b gene.³⁹ Therefore, the 7b antibody test is no more specific or sensitive than the indirect IFA test and this has been substantiated by published studies.^{72,159}

Because of the vagaries of FIP serology, FIP antibody testing should also not be used as a means to control or eliminate FIP from catteries. Vast amounts of money are spent each year by cattery owners on FIP testing. In almost all cases, the results are non-interpretable, even by the veterinarians ordering the testing. Virtually all catteries having six to eight cats and an active breeding program will have FECV in their cattery and 50–80% or more of their animals will have titers of 1:100 or greater (usually 1:25–1:1600). Cattery testing usually confirms what is already known, that FECV is enzootic in the cattery. Antibody titers do not answer the critical questions: (1) do any of the cats actually have FIP, (2) are any of the cats subclinically infected with FIPV, (3) will a particular cat develop FIP in the future, and (4) which cats are shedding FECV? Over- and mis-interpretation of various coronavirus antibody tests result in considerable mortality from senseless euthanasia of healthy cats and undue emotional and financial stress.

Serology has also been applied to the diagnosis of the neurologic form of FIP. Foley et al⁹² observed what they believed to be specific FCoV antibody production within the CNS. They found that the most useful ante-mortem indicators of neurologic FIP were positive IgG anti-coronavirus antibody titer in the CSF, high serum total protein concentration, and magnetic resonance imaging (MRI) findings suggesting periventricular contrast enhancement, ventricular dilatation and hydrocephalus. The diagnostic value of positive anti-coronavirus antibody titers in CSF was later questioned by Boettcher et al.¹⁵¹ They collected CSF from four clinical groups: (1) cats with FIP involving the CNS ($n = 10$); (2) cats with FIP not involving the CNS ($n = 13$); (3) cats with CNS disorders caused by diseases other than FIP ($n = 29$); and (4) cats with diseases other than FIP and not involving the CNS ($n = 15$). CSF was evaluated for concentrations of erythrocytes, leukocytes, and total protein. Anti-coronavirus IgG was measured in CSF and serum by indirect IFA. CSF IgG (1:32–1:4096) was detected in 12 cats, including six cats with neurologic manifestation of FIP, four cats with FIP not involving the CNS, and two cats with brain tumors. CSF IgG was detected only in cats with correspondingly high serum IgG titers (1:4096–1:16,384) and significantly correlated with serum IgG titers. In another attempt to measure local CNS antibody production in cats with FIP, Steinberg et al¹⁶⁰ used an albumin quotient and IgG index to determine whether proteins in the CSF were of blood or local origin. Neither the albumin

quotient nor IgG index identified a pattern consistent with intrathecal IgG synthesis in cats with the CNS form of FIP. The conclusion of these various studies is that coronavirus antibodies will enter the CSF when they are at very high levels in the serum; high serum titers are likely to be associated the dry form of FIP,¹⁵ most neurologic cases of FIP are of the dry type (Table 2); therefore, positive FCoV antibody titers in the CSF are likely to be associated with FIP.

Tests for the presence of FIPV RNA have been developed, but suffer from many of the same weaknesses as serology. Some of the more popular PCR based tests are based on the lack of the 7b gene in the FECV prototype WSU-79-1683 and its presence in the FIPV prototype WSU-79-1146. As mentioned above, the lack of the 7b gene in this one isolate is an artifact, probably of tissue culture adaptation. Therefore, PCR tests based on genetic differences between WSU-79-1146 and WSU-79-1683 are invalid. Moreover, PCR tests are notoriously susceptible to laboratory contamination with the DNA products of amplification. Many commercial laboratories do these procedures in an uncontrolled manner. In an attempt to increase specificity and sensitivity, a PCR was developed that would only detect forms of the viral RNA that were present during its replication stage.¹⁶¹ The rationale was that replicating forms of the viral RNA would only be found in the blood of cats with FIP. The test was designed to amplify subgenomic mRNA of the highly conserved M gene. The test was applied to 424 healthy and 651 cats suspected of having FIP. Almost one-half of the diseased cats were positive for the replicating form of FCoV mRNA in their peripheral blood cells, whereas only 5% of healthy cats tested positive. Seventy-five of 81 cats (93%) with post-mortem confirmed FIP tested positive, whereas 17 non-FIP cases all tested negative. Such optimistic results were not found when the same test was applied to another group of cats. In this study, 26 blood samples were collected from 25 healthy cats and one cat with clinical signs suggestive of FIP, namely, fever, weight loss, enlarged abdomen, and ascites.¹³⁴ Blood samples were then tested for replicating FCoV messenger RNA by the procedure of Simons et al.¹⁶¹ Fourteen (54%) of the cats were positive for FCoV including the cat with clinical disease, but a high rate of positivity was also observed among healthy cats, suggesting that feline coronaviruses may be present in the blood samples from healthy cats as well as cats with clinical FIP. This suggestion has been confirmed for healthy cats by others.^{43,138} These conflicting findings call into question the value of PCR for testing of blood. However, RT-PCR has accurately differentiated FIP effusions from effusions of other causes.¹⁵⁸ The problem of laboratory contamination with PCR products can be virtually eliminated by using a technique called real-time PCR (TaqMan).

Some clinicians and cattery owners will test for FCoV in feces by PCR in an attempt to identify FECV carriers within groups of cats and eliminate

shedders from the environment as a means to prevent FIP losses. The FECV is shed at high levels in the feces, but the carrier rate is 40–80% or higher in many multi-cat populations and shedding is intermittent and infections recurrent (reviewed by Pedersen et al 2008).²⁵ PCR inhibitors have been described in feces, so it is important to purify viral RNA using certain methods.¹⁶² Such testing is expensive, and only a few laboratories can do it reliably on a commercial basis. However, in the final analysis, it is virtually impossible to maintain a group of cats free of the virus, even if the infection can be eliminated, without strict quarantine facilities and measures, as well restricting the movement of cats and people between cat populations (see [Treatment and prevention](#)).

Rivalta's test has touted for the diagnosis of wet FIP.¹⁵⁸ A test tube is filled with distilled water and one drop of 98% acetic acid is added, followed by a drop of the peritoneal or pleural effusion. If the drop dissipates in the solution, the test is negative, and if the drop retains its shape, the test is positive. A negative Rivalta's test is reportedly 97% accurate in ruling out FIP, while a positive test is 86% accurate in ruling in FIP. This author sees no improvement in diagnostic value of this test over routine gross, microscopic, and biochemical analysis of the fluid, but it is a simple and cheap supportive test.

Several indirect tests, usually based on the levels of certain inflammatory proteins or byproducts (acute phase reactants), have been used to detect inflammatory conditions in cats, and in particular FIP (reviewed by Paltrinieri et al).⁵⁰ Alpha-1-acid glycoprotein (AGP) is an acute phase protein that increases in concentration in infectious and inflammatory conditions. The serum and peritoneal fluid concentrations of AGP has been found useful in the diagnosis of FIP.^{163,164} Amyloid A and AGP both increase a few hours after the inflammatory stimulus and remain elevated for as long as the inflammation persists and have been evaluated in cats. Serum AGP levels have also been used to study FIP in groups of cats.¹⁶⁵ Serum AGP concentrations were observed to fluctuate over time in clinically healthy cats from catteries with the highest prevalence of FIP and significantly increased just before an outbreak of FIP. Although increased levels of AGP and other inflammatory proteins are particularly common in cats with FIP,¹⁶⁴ they are not specific. Levels of AGP are usually high in cats with FIP and other inflammatory diseases; moderate serum AGP levels (1.5–2 mg/ml) can discriminate cats with FIP from other diseases that have a low pretest probability, while high serum AGP levels (>1.5–3 mg/ml) are not usually seen in cats with diseases other than FIP.^{164,166} However, the specificity of increased AGP levels has been questioned by others.¹⁶⁶ The potential value of raised levels of the acute phase reactants, AGP and haptoglobin in the diagnosis of FIP was examined in cats with confirmed FIP and in cats with other conditions. Levels of AGP greater than 1.5 g/l in serum, plasma

or effusion samples were found to be of value in distinguishing field cases of FIP from cats with similar clinical signs and differentiated these two groups of cats more effectively than the albumin:globulin ratio. The concentration of haptoglobin was higher in cats with FIP than in the group of healthy cats, but not sufficiently to be of diagnostic value. Serum samples from FIV-infected cats also had significantly elevated levels of AGP and haptoglobin, illustrating that raised levels of these inflammatory proteins are not pathognomonic for FIP. Modifications of AGP have also been tested to increase its specificity.¹⁶⁷ AGP in humans is heavily glycosylated and undergoes several modifications of its glycan moiety during acute and chronic inflammatory processes. Using human test modifications, feline AGP had very little L-fucose residues on its surface and its branching degree was very low in normal and in several pathological conditions. In contrast, feline AGP underwent several modifications during acute FIP, including decreased expression of both α (2–6)-linked and α (2–3)-linked sialic acid (76% and 44%, respectively) when compared to non-pathological feline AGP. The possible role of some acute phase (inflammatory) proteins and immunoglobulins in both the pathogenesis and diagnosis of FIP was also reported by Giordano et al.¹⁶⁸ Serum protein electrophoresis and the concentration of haptoglobin (Hp), serum amyloid A (SAA), AGP, IgG and IgM were evaluated in healthy coronavirus-exposed cats and cats with FIP. The highest concentration of acute phase proteins was detected in affected cats, confirming the role of these proteins in supporting a clinical diagnosis of FIP. Interestingly, healthy coronavirus-exposed cats also had increased acute phase proteins at the same time that members of the group developed FIP appeared in the group. However, this increase persisted only in cats that developed FIP. It is apparent from these various studies that levels of AGP, as well as other inflammatory proteins, change dramatically in FIP, but that none of these changes are definitive in their own right.

MRI has proven useful in confirming the presence of inflammatory neurologic disease indicated by CSF analysis.¹⁶⁹ Fourteen cats with inflammatory diseases affecting the CNS were reviewed, including eight cats with FIP and two cats with toxoplasmosis. Abnormalities affecting the CNS were observed in MR images in 10/14 (71%) cats. Intracranial lesions appeared as slightly hypointense foci in T1-weighted images in two (14%) cats, as hyperintense foci in T2-weighted images in seven (50%) cats, and as hyperintense foci after intravenous administration of a gadolinium-based contrast medium in 10 (71%) cats. In six cats with lesions in T1- and/or T2-weighted images, additional lesions were visible in T1-weighted images obtained after gadolinium-based contrast medium administration. In three cats, lesions were visible only after contrast medium administration. The MRI in this study did not detect all cases of CNS inflammation in a population of cats with

inflammatory CSF. However, it did add information on the location of lesions, which can be important in differentiating FIP from other inflammatory conditions. This substantiated the conclusions of an earlier MRI study on cats with neurologic FIP.⁹² Sixteen domestic cats with confirmed neurologic FIP and eight control cats with non-neurologic FIP were studied pre- and ante-mortem. The MRI imaging demonstrated periventricular contrast enhancement, ventricular dilatation, and hydrocephalus in cats with neurologic FIP.

The present gold standard for FIP diagnosis is immunohistochemistry on effusions or lesions containing infected macrophages. Monoclonal or polyclonal antibodies that are highly FCoV specific, and that will react well with formalin fixed tissues, have been used.¹⁷⁰ Sections of lesions or cell pellets from ascetic or pleural fluids can be directly examined for virus using fluorescein or horseradish peroxidase polyclonal or monoclonal antibodies. Detection of coronavirus antigen in FIP effusions is very specific, but less sensitive than detection of viral antigens in characteristic FIP parenchymal lesions. Hirschberger et al.¹⁴⁹ identified antigen in 34/49 confirmed FIP effusions, whereas 50 effusions due to other causes were negative. The specificity of immunohistochemistry is a factor of the poly- or monoclonal antibodies used and the characteristic localization of FIPV antigen within macrophages.^{146,170} The sensitivity of the test depends on having infected macrophages in the tissues or exudate cells on the slides. For this reason, random biopsy of liver or kidney of cats with FIP often fail to yield FIPV antigen by immunohistochemistry,¹⁷¹ and the same would be true of real-time PCR. Sensitivity is five to 10 times greater with fluorescein than horseradish peroxidase staining, but the latter has the advantage of using formalin fixed and paraffin embedded tissues, while the former requires frozen sections of tissues. Both can be used with equal ease on slides of cells harvested from effusions and acetone fixed.

Virus isolation in tissue culture has not been yet possible for FECVs and is difficult for most field strains of FIPV. Serotype II FIPVs seem to grow better in tissue culture, and will often grow on both Crandell feline kidney (CrFK) and Fcwf-4 cells. The latter cell line is of macrophage lineage¹³ and is the preferred cell line for the isolation of serotype I FIPVs.^{12,84} The cost and low yield of cell culture isolation prohibits its routine application to clinical diagnosis.

Following the introduction of tests for detection of FeLV infection, one-third or more of cats with FIP were found to have concomitant FeLV infections.^{120,172} With elimination of FeLV from many catteries and pet cat households, and the steady decline in the incidence of FeLV in the entire cat population, the proportion of cats with FIP and concurrent FeLV infections has greatly decreased. At the present, virtually all cases of FIP in purebred cattery-bred cats are FeLV negative, and FeLV infection is detected in 10% or less of domestic pet cats with FIP.

Pathologic features

The principle lesion of effusive FIP is the pyogranuloma^{3,135,173} and the infection has been characterized as a distinct form of vasculitis (ie, phlebitis).¹⁷⁴ The pyogranulomas of wet FIP are particularly prevalent in the abdomen and can literally cover the serosal surfaces of abdominal organs (Fig 11). They range from microscopic to several millimeters in size, and can sometimes become confluent as a fibrinous sheet (Fig 12). The pyogranulomas of effusive FIP tend to follow the course of the cranial mesenteric artery and are, therefore, concentrated in the omentum and on serosal surfaces of the abdominal viscera (Table 1). The omentum is often thickened with edema, inflammatory infiltrate and necrosis and retracted into a compact mass (Fig 12). Lesions are less common in the thorax and are centered on the pleura and pericardium (Table 1).

Pyogranulomas are made up of central aggregates of macrophages adjacent to small venules and surrounded by a rich inflammatory exudate containing mainly neutrophils and macrophages with a scattering of plasma cells and T-lymphocytes¹⁷⁵ (Fig 13). Almost all macrophages within pyogranulomas of cats with wet FIP contain viral antigen at a high concentration (Fig 14). Considerable amounts of fibrin and protein-rich fluid are also deposited within and around the lesions and necrosis is often evident.¹³⁵ Though the pyogranulomatous process is usually surface oriented, focal lesions of phlebitis and a mixed inflammatory-cell infiltrate may be seen deep in underlying muscle or organ parenchyma.

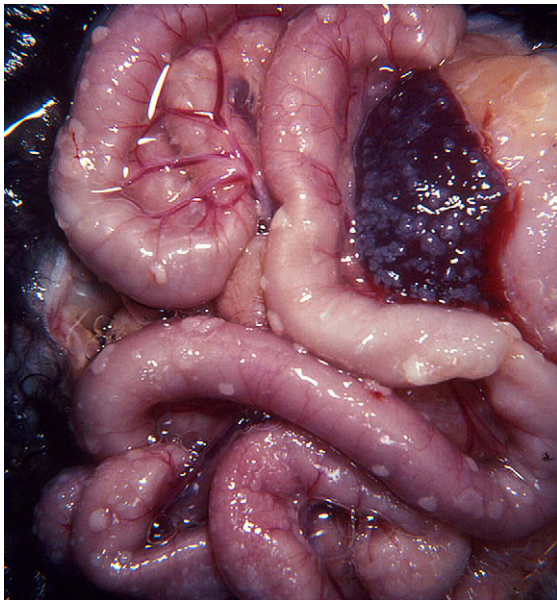


Fig 11. Abdominal viscera of a cat with effusive FIP. The serosal surface of the intestines and spleen are covered with punctate, coalescing fibrinous plaques, the classic pyogranulomas of effusive FIP. Some peritoneal effusion is evident, although most has been removed.

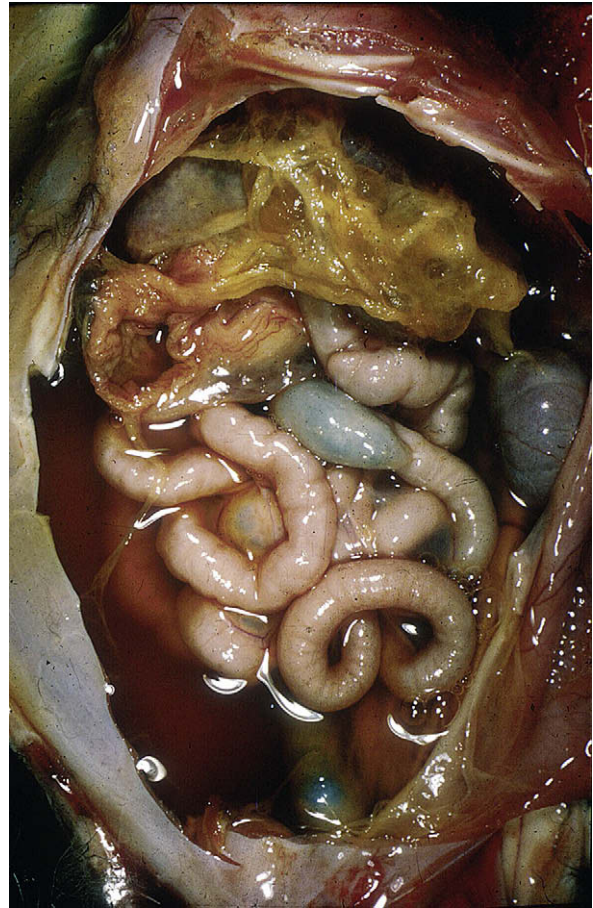


Fig 12. Abdominal viscera of a cat with effusive FIP. The serosal surface of the intestines and spleen is covered with punctate, coalescing fibrinous plaques, the classic pyogranulomas of effusive FIP. Some peritoneal effusion remains, though most has been removed.

The lesions of dry FIP have been also referred to as pyogranulomas, but they more closely resemble classical granulomas in their outward appearance, especially those in the abdomen (Figs 3–6). Lesions of dry FIP typically contain foci of macrophages around vessels, reminiscent of the lesions of effusive FIP. However, these foci are surrounded by dense infiltrates of lymphocytes (mainly B-cells) and plasma cells that extend into surrounding tissues, as seen in classical granulomas (Fig 15). Edema, hyperemia, necrosis, fibrin deposition and protein exudation are not as pronounced as in the pyogranulomatous lesions of effusive FIP.¹⁷⁵

Abdominal/pleural lesions of dry FIP have been described as extraperitoneal,⁶ but probably originated in the serosa or pleura and invaded along vessels into the underlying parenchyma. Granulomas, especially in the abdomen, can vary in size from microscopic to several centimeters in diameter, and larger lesions can be mistaken outwardly for cancers such as lymphoma.^{6,115} Similar to the pyogranulomas of wet FIP, the granulomas of dry FIP are also most apt to occur

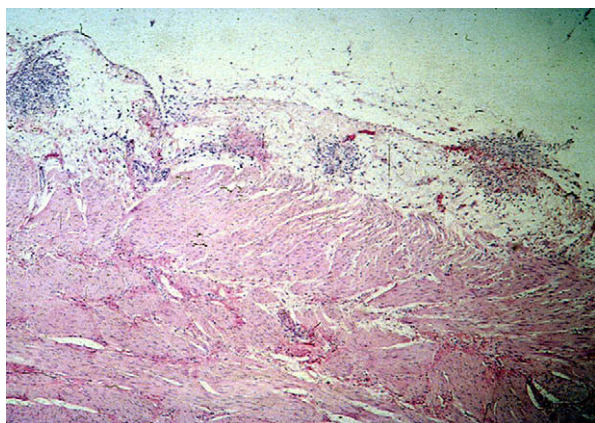


Fig 13. Abdominal viscera of a cat with effusive FIP. The serosal surface of the intestines and spleen is covered with punctate, coalescing fibrinous plaques, the classic pyogranulomas of effusive FIP. Some peritoneal effusion remains, though most has been removed.

in the abdomen (kidneys, mesenteric lymph nodes, liver, caecum/colon), and are uncommon in the chest cavity (Table 2) (Figs 3–7). Lesions in the eyes and CNS are much more frequently seen in cats with dry than wet FIP, and may occur in the absence or presence of abdominal/thoracic lesions. Lesions within the brain, spinal cord and eyes tend to be smaller than those found in the abdomen and are more similar in nature to the lesions of effusive FIP. CNS lesions are centered in the meninges and ependyma and also extend down into the underlying brain, spinal cord, or spinal nerves. Lesions are particularly common in the posterior-ventral aspect of the brain.

Ocular lesions of FIP have been well studied.¹⁰⁸ The most common morphologic feature is a lymphocytic and plasmacytic anterior uveal infiltrate, which is either diffuse or nodular. This is manifested grossly by swelling and discoloration of the iris, with foci of granulomatous involvement sometimes observed. Keratic or mutton-fat precipitates are common on the back sides of the cornea (Fig 9). These precipitates are made up mainly of macrophages, other inflammatory cells, and fibrin that have exuded from the inflamed uveal tract.

Lymphoid lesions are common in effusive and non-effusive FIP. Splenic enlargement may be due to histiocytic and plasmacytic infiltration of the red pulp, hyperplasia of lymphoid elements in the white pulp, necrotizing splenitis with fibrin deposition and polymorphonuclear cell infiltrates (more common in wet FIP), or by more organized pyogranulomatous reactions (more common in dry FIP). Gross lymph node enlargement is usually limited to thoracic and abdominal nodes with lesions resembling those described for the spleen. Kipar et al^{115,176} reported on lymphoid organ lesions in cats with FIP and cats that had resisted experimental infection. In cats with FIP, the precardial mediastinum (including site of the thymus) and mesenteric

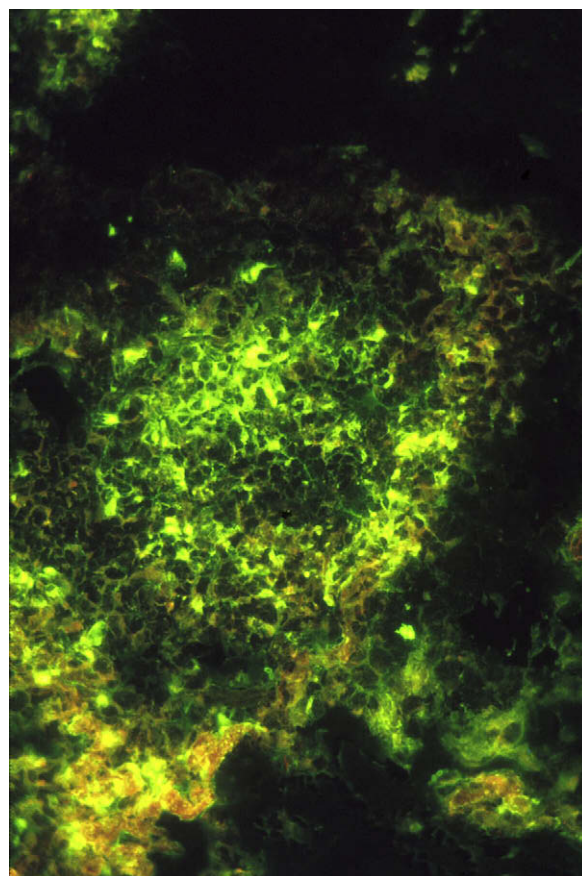


Fig 14. Immunofluorescent antibody staining for feline coronavirus antigen of a pyogranuloma in the serosa of the bladder. Antigen is concentrated in a high proportion of the macrophages within focal pyogranulomas.

lymph node parenchyma were often affected by granulomatous-necrotizing processes. In general, lymphoid tissues showed T- and B-cell depletion, often including massive to complete thymic involution or atrophy. In some cases, the number of apoptotic lymphocytes was increased in lymphoid follicles as well as in T-cell zones. The number of macrophages was increased in the splenic red pulp. In contrast, the FIPV-exposed cats without FIP generally showed lymphoid hyperplasia.

Fluorescent or immunoperoxidase antibody staining of tissue sections from cats with both forms of the disease shows FIPV in the lesions.^{139,175} In effusive FIP, a large amount of viral antigen is contained in phagocytic cells that make up a large part of the pyogranulomas (Fig 14).^{12,135,175,177} Less viral antigen is present in lesions of non-effusive FIP (Fig 16) and more in lesions of effusive FIP (Fig 14).¹⁷⁵ Lesions associated with necrosis (mainly pyogranulomas), therefore contain more virus than lesions without necrosis (mainly granulomas).¹⁷⁵ Some plasma cells within lesions are found to be producing coronavirus specific antibodies.¹⁷⁵ Lesions, especially pyogranulomas of effusive FIP, also demonstrate large amounts of bound

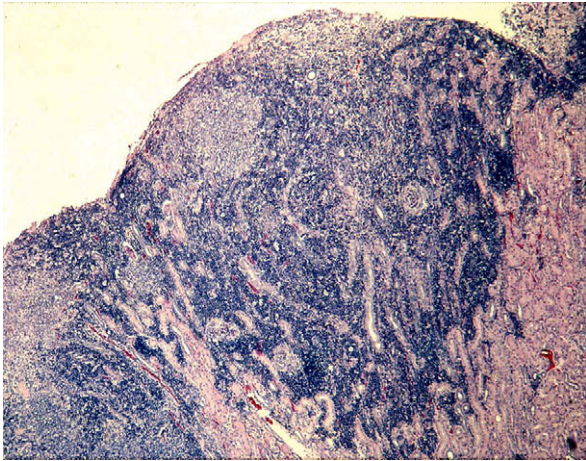


Fig 15. Microscopic view of a granulomatous lesion from a cat with non-effusive FIP. Distinct focal accumulations of macrophages are seen just under the capsule of the kidney. These foci are surrounded by dense accumulations of lymphocytes and plasma cells extending downward into the parenchyma.

complement and Ig, indicating their Arthus-like nature (Figs 17 and 18).

Experimental infection

Experimental infection studies were initially concentrated on highly virulent strains of FIPV such as 79-1146 (-Nor15 and -DF2 are identical to 79-1146). Studies with such strains give the impression that virtually all cats infected with FIPV will develop disease and die (Table 3). However, FIPV-79-1146 is atypical, not only in its virulence, but because of its ease of growth in non-macrophage type cells such as CrFK fibroblast cells and its CCV-like spike protein. The most virulent serotype I isolates are FIPV-UCD1 and FIPV-TN406, but they are still less virulent than

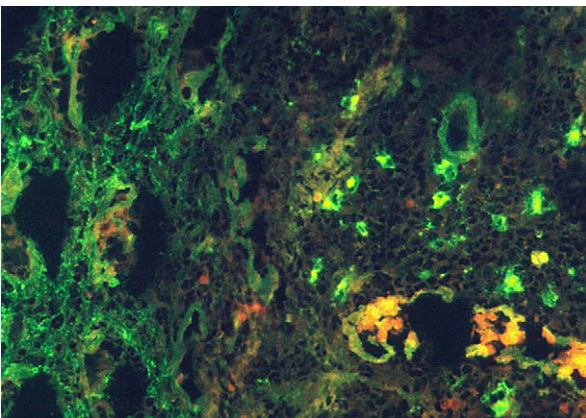


Fig 16. Immunofluorescent staining of a foci from the kidney section shown in Fig 15. A much smaller proportion of the macrophages stain for feline coronavirus antigen than in the pyrogranulomas of effusive FIP (Fig 14).

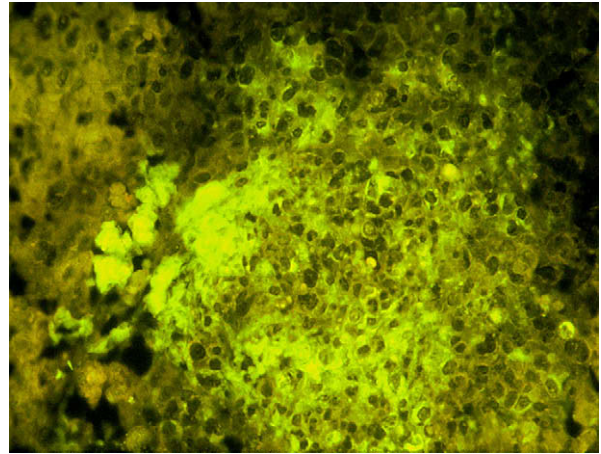


Fig 17. Immunofluorescent antibody staining for feline IgG. Accumulations of IgG are seen both within and without macrophages, mainly within and adjacent to pyrogranulomas. Some plasma cells also contain IgG.

FIPV-79-1146. Interestingly, outbreaks of FIP with extremely high morbidity and mortality are very uncommon in nature, suggesting that such highly virulent laboratory strains as FIPV-79-1146, -UCD1 and -TN406 are atypical. This is borne out by experimental infection studies with yet other isolates of FIPV (Table 3).⁸⁴ Oral (PO) infection is least likely to cause disease; intratracheal/intranasal (IT/IN) infection is intermediate, while intraperitoneal (IP) is the most efficient.

The first experimental evidence of the relationship between FECVs and FIPVs came from studies of enzootic FECV infection in a colony of conventional cats used for FeLV research.^{119,121} The presence of an FCoV among this colony of cats did not become evident until cats were horizontally exposed to FeLV by natural contact and began to die of FIP.^{119,121} The presence of two virtually indistinguishable coronaviruses among these cats, one infecting the gut and causing little disease and another capable of causing FIP, was later reported by Pedersen et al.²⁷ This study resulted in the isolation of FECV-UCD. This relationship was given further credence by an inadvertent introduction of an FECV, named FECV-Rogers-Morris or FECV-RM, into a barrier contained research colonies of specific pathogen-free (SPF) cats.¹⁷⁸ A few cases of FIP over several years among hundreds of kittens was the first indication that the colony was infected. The FECV → FIPV mutation was further confirmed by infecting cats with long-term FIV infections and a cohort of non-FIV-infected siblings with FECV-RM.²⁸ It was hypothesized that an FIV immunocompromised host would replicate FECV at higher levels and lead to a greater chance of mutation, and that the mutant virus would be more likely to manifest itself in an immune suppressed host. The FECV-RM did replicate to higher levels in the FIV-infected cats and about 20% died of FIP within 8–10 weeks; no deaths from FIP were seen in a cohort of non-FIV-infected siblings. This study established that the FIPV mutation is

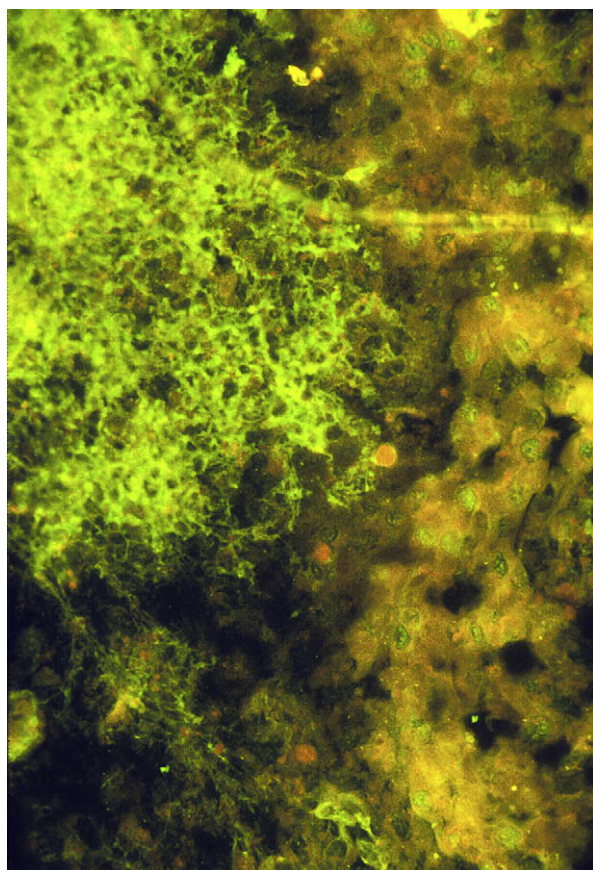


Fig 18. Immunofluorescent antibody staining for feline C3. Complement staining of macrophages has a web-like appearance.

frequent during primary FECV infection and that the immune status of the cat is important in determining the clinical outcome of this mutation.

Conclusive studies on age susceptibility have not been undertaken. While most studies have used kittens or younger cats, there is no direct evidence that kittens are more susceptible to infection. There is, however, indirect evidence. Cats vaccinated before 16 weeks of age with an attenuated live FIP vaccine were apparently more susceptible to challenge-exposure and less responsive to vaccination (NC Pedersen, UC Davis, personal observation, 2008) as deduced from Christianson et al.¹⁷⁹ and Gerber et al.¹⁸⁰ Sixteen weeks is also a time when the immune system of cats has reached a near-adult level of maturation to this and other infections.¹⁸¹

Tissue culture-adapted strains of FIPV are often mixtures of viruses, and the predominant virus may not be the most virulent. Variants may arise while in culture, or may be present in the cat prior to culturing (NC Pedersen, unpublished observation, 2008). Three FIPV strains from Japan, KUK-H, M91-266 and M91-267, were examined for biologic properties and virulence.¹⁸² Both large and small plaque forming viruses were identified in culture for each isolate.

Non-plaque purified virus of each strain induced FIP in 50%, 67% and 89% of cats, respectively. Interestingly, only 29% of kittens inoculated with the large plaques from one of these isolates (KUK-H) developed FIP, while 80% of cats inoculated with the small plaque form succumbed to FIP. The TN406 strain of FIPV exists in a low and high passage form. The low passage form is very virulent, while the high passage form is non-virulent.⁸³ This same reversion to non-virulence occurred in a culture of FIPV-UCD1.¹⁸³ The virulent form in vivo may also not be the predominant form in vitro. For instance, it is difficult to re-isolate FIPV-UCD1 in a form that will grow in tissue culture, even though the cats were inoculated with tissue culture-adapted virus (NC Pedersen, UC Davis, personal observation, 2008). We have also studied cats with naturally acquired FIP that have had two genetic variants in their tissues at the same time (NC Pedersen, UC Davis, personal observation, 2008).

The incubation period and clinical outcome of FIPV infection depends both on the strain of the virus and immunologic responsiveness of the host. Experimental studies using serotype I strains of FIPV, of low to moderate virulence, best reflect what happens in nature. Tissue culture strains of this type include FIPV-UCD1 and FIPV-Black_(low passage) (FIPV-TN406), which are moderately virulent,^{12,83} and strains such as FIPV-UCD2, -UCD3, -UCD4 and -UCD8 that are even less virulent (Table 3).^{84,183} Even though low virulence laboratory strains of FIPV exist, most experimental studies are with high virulence serotype I strains such as FIPV-UCD1, or serotype II strains such as FIPV-79-1146. Almost all cats inoculated with high virulence isolates, regardless of route, develop an initial fever spike at 24–72 h, followed by a second and prolonged fever starting 10–21 days or longer after inoculation, at the time antibody appears. The subsequent disease course is almost always of the effusive type and animals are in a terminal stage within 1–3 weeks. The sites of early replication of FIPV were studied following oral inoculation of SPF cats with the Wellcome strain of FIPV grown in cell cultures, a moderately virulent serotype I virus.¹⁸⁴ Viral antigen was first detected by immunofluorescence in the tonsils and small intestine within 24 h of inoculation, and was later found in the caecum, colon, mesenteric lymph nodes and liver. Virus was recovered from the oropharynx and the feces from as early as the second day after inoculation, and shedding continued until euthanasia. However, histological changes in the gut did not appear until relatively late in the course of infection. Histological changes appeared to correlate with the appearance of outward signs of disease, which is often 2 weeks later than the appearance of virus in the feces and oropharynx.¹⁸⁵

The appearance of a sustained fever usually coincides with the appearance of detectable levels of FIPV antibodies by the indirect immunofluorescent antibody technique,^{135,139,177} which in naïve cats is 10–16 days after infection. Early studies with FIPV strains such as FIPV-UCD1 demonstrated

a phenomenon of immune enhancement. Cats previously infected with an FECV, a non-disease causing FIPV, or cats passively given FCoV antibodies from healthy or FIP-diseased cats, developed a fever within 48–72 h and rapidly died.^{139,140} The FIPV antigen in ‘antibody primed’ cats was present in macrophages and large mononuclear cells in the tracheobronchial lymph nodes, lungs, and trachea on postchallenge-exposure day (PCD) 2; in the liver and spleen on PCD 3; in the kidneys and omentum on PCD 4; and subsequently in the nasal turbinates, thoracic and abdominal lymph nodes, thymus, bone marrow, parotid salivary gland, eyes, and brain.^{135,177} Initial antiviral immunofluorescence on PCD 2 coincided with the onset of viremia and vascular lesions. Systemic lesions characterized by perivascular necrotizing pyogranulomatous inflammation, phlebitis and thrombosis, fibrinous serositis, and generalized lymphoid necrosis developed on PCD 3 and 4. Coronavirus-like particles were observed by electron microscopy in the cytoplasmic vacuoles or the smooth endoplasmic reticulum of degenerating macrophages in inflammatory lesions. The timing of viremia was delayed in kittens that were seronegative at the time of FIPV infection; antiviral immunofluorescence in tracheobronchial lymph nodes was first detected on PCD 5, and viremia occurred on PCD 6.^{135,177} Systemic necrotizing lesions, comparable with those observed in seropositive kittens on PCD 3 or 4, did not occur in seronegative kittens until PCD 13 or 16. In both groups of kittens, initial viral infection in regional lymphoreticular tissue was followed by viremia and infection of macrophages in reticuloendothelial organs (liver, spleen, lymph nodes) and perivascular locations.

Experimental studies of FIPV infection have been recently advanced by the development of molecular clones of the virus. As in studies with other viruses, infectious clones allow genes to be altered, switched and deleted to study their effects on infectivity, virulence and other disease properties. Molecular clones have been constructed mainly by a process called reverse genetics, and at least three cloned viruses presently exist.^{186,187} Some of these cloned FIPVs, such as one derived from the highly virulent FIPV-79-1146 strain, retain their virulence when inoculated into experimental cats.¹⁸⁶

Treatment and prevention

It must be stated at the onset that no treatment has proven effective in curing cats of FIP, in spite of the claims. Cats that develop FIP inevitably die of their disease in days, weeks or months. The reason for these numerous false claims is uncertain, but spontaneous remissions may account for at least some reports and misdiagnosis for the remainder. Cats with ocular signs and no other systemic manifestations of FIP have occasionally gone into remission with just symptomatic treatment. Cats with chronic fever, enlarged mesenteric lymph nodes that were histologically

compatible with FIP, and high coronavirus titers, have gone into remission without treatment. Some cats without overt signs of FIP have demonstrated fibrous lesions on the spleen and liver when necropsied for other reasons, indicating a previous bout of FIP. Small quiescent lesions in the spleen and mesenteric lymph nodes have also been found in otherwise healthy cats upon routine ovariohysterectomies. Therefore, spontaneous remissions occur and at least some of these natural responses may have fortuitously coincided with various treatments. Cures were first reported with tylosin and prednisolone,¹⁸⁸ sparking a decade of tylosin use for treatment of FIP. However, tylosin has no effect on FIP. Interestingly, a significant proportion of cats with FIP are still treated with an antibiotic of one type or the other. Some cats have gone into remission after use of prednisolone and phenylalanine mustard or cyclophosphamide.¹⁵ Another cat was successfully ‘treated’ with prednisolone and phenylalanine mustard.¹¹⁶ No immunosuppressive drug regimen has withstood the test of time.

A number of other equally dubious non-specific treatments have been used for FIP, almost all with insufficient patient numbers, inadequate documentation of infection, or lack of essential placebo controls and double blinding.¹⁸⁹ The FIPV is very sensitive to human α and β interferons in vitro.¹⁹⁰ Feline interferon omega also will inhibit FIPV in vitro and is commercially available in many countries.¹⁹¹ Feline interferon omega reportedly induced complete or partial remissions in two thirds of cats with FIP.¹⁹² However, in a larger and double blinded study, this treatment was found to be totally ineffective.¹⁹³ Various immunosuppressants such as glucocorticoids and cyclophosphamide have been used, but these drugs may prolong life but do not alter the fatal outcome.¹⁸⁹ Immunostimulants, megadoses of vitamins, and numerous nutraceuticals have also been advocated but found to be without merit. Pentoxifylline, a tumor necrosis factor alpha (TNF- α) inhibitor,¹⁹⁴ has been used on cats with FIP based on its benefit in treating some types of human and feline vasculitis.¹⁹⁵ The TNF- α is upregulated in FIP¹⁸³ and FIP is basically a vasculitis. However, this treatment has not proven beneficial on its own and has fallen from use. We have treated one FIP cat with feline IFN- γ and a TNF- α inhibitor (Pentoxifylline) with no beneficial affect.

Effective vaccines have been as elusive as effective treatments. Pedersen¹⁹⁶ hypothesized that the ideal FIPV vaccine should contain a live virus that would persist in the body in a subclinical state, inducing a state of premonition immunity. However, a successful vaccine against FIP has not been developed, even though most have been based on this hypothesis. Cats that survive infection with a progressively increasing dose of virus, starting with sublethal levels, appear to develop a type of immunity.⁸³ However, this approach is not clinically applicable, because as many cats die as become immune, and immunity appears to be tenuous. Some cats that appear to have

resisted disease have developed FIP months or years later, indicating the persistence of subclinical infections. This finding was supported by a subsequent study by Baldwin and Scott.¹⁹⁷ They first immunized cats intratracheally with a sublethal dose of virulent FIPV, followed by a high dose of temperature attenuated virus. Cats demonstrated immunity to an aerosol challenge with highly virulent FIPV but residual lesions were found upon necropsy examination suggesting that immunity was either partial or of the premonition type. Early attempts to use an attenuated live FIPV strain, FIPV-Black_{high passage}, to induce immunity failed to provide protection and even caused immune enhancement. A similar finding was reported later for a virulence attenuated strain of FIPV-UCD1.¹⁸³ The phenomenon of FIPV vaccine induced enhancement has been recently reviewed and is a common theme in many vaccine approaches.¹⁹⁸

A temperature sensitive mutant of FIPV-79-1146, administered intranasally, was later developed and corporate studies showed a high degree of efficacy against challenge with highly virulent FIPV-79-1146.^{179,180} Immunity was ascribed to a local IgA response and systemic cellular response measured by FIPV-induced lymphocyte proliferation. This vaccine is given as two intranasal doses, 3 or more weeks apart, starting at 16 weeks or older. Presumably, efficacy could not be shown for cats vaccinated and/or challenge-exposed at a younger age. This commercial vaccine was studied in the field in a large single building shelter housing a thousand or more cats.^{199,200} Five hundred FIV/FelV negative, FCov antibody negative cats were divided into two groups prior to being put into this environment. One-half got the intranasal live vaccine and one-half was sham vaccinated. The cats were then followed for 16 months. Overall deaths in both groups were the same. However, two cats in the vaccinated group developed FIP during the 16 months and eight non-vaccinated cats succumbed to the disease. Protection in this study was not convincing and the validity of using the vaccine only on coronavirus negative cats and measuring protection over a limited period of time were questioned.²⁰¹ Hoskins et al²⁰² vaccinated 20 SPF cats intranasally at 16 and 19 weeks of age, and added 20 non-vaccinated controls. All 40 cats were then challenge-exposed orally at 23 weeks of age with FIPV-DF2 (ie, FIPV-79-1146). One vaccinated and five non-vaccinated cats developed effusive FIP and were euthanased. However, six of the remaining vaccinates and 12 of the remaining controls had histologic evidence of FIP when necropsied 8 weeks later. Wolf²⁰¹ criticized this study for using a homologous challenge strain and for only following the cats for 8 weeks. In a second field study, the vaccine failed to prevent FIP in cattery kittens immunized in the presence of pre-existing FECV antibodies.²⁰³ The issues of serotype specificity (ie, the vaccine is against serotype II, while most field isolates are serotype I), interference with maternal antibodies, the need to withhold

vaccination until at least 16 weeks, and the relatively poor efficacy are serious limitations. This vaccine is still marketed, and is used by some veterinary practitioners. It has proven safe over a long period of use and does not appear to enhance disease.²⁰⁰ However, its degree of effectiveness in the general cat population, where the incidence of FIP is very low, and in catteries and multi-cat households where virtually all 16 week olds are already seropositive and therefore non-responsive, is highly questionable. Serotype cross-reactivity is also an issue. Cross protection between closely related viruses, such as TGE virus or CCV, and FIPV either does not occur or is weak.^{204–206} Cross protection between various isolates of the same serotype may also vary.²⁰⁷ Cats infected with FIPV-UCD2 neither became ill nor developed protective immunity against challenge-exposure with more virulent strains. The FIPV-UCD3 recovered cats tend to be immune to challenge with FIPV-UCD1, while FIPV-UCD4 recovered cats do not have good protective immunity to FIPV-UCD1. These are all serotype I FIPVs.

There have been a number of different potential vaccines based on recombinant technology described in the literature since 1990. A genetically engineered vaccinia virus expressing the envelope protein of FIPV has been tested²⁰⁸; it enhanced virulent FIPV infection rather than protecting cats. Wasmoen et al²⁰⁹ developed a recombinant raccoon poxvirus that expressed the gene encoding the nucleocapsid protein of FIPV and used it as a vaccine. Cats were parenterally or orally vaccinated twice, 3 weeks apart, and then infected orally with FECV to sensitize them to virulent FIPV. Three weeks later, the cats were orally challenged with FIPV; 4/5 (80%) of the non-vaccinated controls succumbed to FIP, while 0/5 cats vaccinated subcutaneously with the raccoon recombinant poxvirus developed FIP. One of the five cats in this latter group died following a second FIPV challenge, suggesting immunity was of the premonition type. Vaccination induced serum antibody responses to FIPV nucleocapsid protein, but they were not neutralizing. This suggested that the protective immune response involved a mechanism other than neutralizing antibodies to the spike glycoprotein or that FECV boosting was important for immunity. The subsequent fate of this vaccine approach is unknown. In another study, the spike gene of FECV-79-1683 was cloned into vaccinia virus and used as an expression vector vaccine.²¹⁰ Vaccinated cats developed neutralizing antibodies, but kittens vaccinated with the recombinant vaccinia virus died earlier than animals vaccinated with native vaccinia virus alone. A plasmid vaccine containing the membrane (M) and nucleocapsid (N) genes failed to protect kittens against a challenge infection with FIPV,²¹¹ while a vaccinia virus expressing the M protein of FIPV failed to protect cats against FIPV-79-1146.²¹² A vaccine made up of a cell lysate of recombinant baculovirus-expressed FIPV-KU-2 nucleocapsid protein protected 6/8 vaccinates versus 1/8 of cats immunized with a control antigen.²¹³

Hajjema et al.²¹⁴ reported successful vaccination of cats against a homologous virus challenge of cats with a live FIPV that has been attenuated by deletion of the 3a-c, and to lesser extent 7ab gene clusters. No follow-up research has been reported on these latter two vaccine approaches.

Antiviral drug therapy has become increasingly important in a number of viral diseases such as human immunodeficiency virus and human influenza virus. Ribavarin, which is strongly inhibitory of FIPV in vitro,²¹⁵ is not effective in vivo.²¹⁶ This dichotomy between in vitro and in vivo inhibition is mirrored by recent experience with the human severe acute respiratory syndrome (SARS) coronavirus.²¹⁷ Sixteen different compounds were subsequently tested for their ability to inhibit FCoV replication in vitro; six of the compounds were found to reduce the virus titers by 0.401 to 0.833 log₁₀ ($P < 0.05$), using cytopathic effect as the endpoint.²¹⁸ The 50% effective dose (ED₅₀) levels for these six compounds was pyrazofuin > 6-azauridine > 3-deazaguanosine > hygromycin B > fusidic acid > dipyrindamole, respectively. Compounds that had no statistically significant effect on FIPV in the same assay were caffeic acid, carbodine, 3-deazauridine, 5-fluoroorotic acid, 5-fluorouracil, D(+)-glucosamine, indomethacin, D-penicillamine, rhodamine and taurine. No subsequent in vivo studies were reported on the compounds that were inhibitory in vitro. The more recent appearance of SARS in humans has greatly increased interest and knowledge of other potential anti-coronaviral drugs. A wide variety of pyridine N-oxide derivatives have been found to be inhibitory against FCoV (FIPV strain) and human SARS-CoV (Frankfurt strain-1) in CrFK and simian kidney (Vero) cell cultures, respectively.²¹⁹ The most selective compounds were active at a high microgram per liter range and non-toxic at 50–100 mg/l. One of the most active and selective compounds tested was shown to inhibit FCoV replication at the transcriptional level. Balzarini et al.²²⁰ also demonstrated inhibition of FIP and human SARS coronaviruses by semisynthetic derivatives of glycopeptide antibiotics including vancomycin, eremomycin, teicoplanin, ristocetin A and DA-40926. The 50% effective concentrations (EC₅₀) for the most active derivatives were in the lower micromolar range. The EC₅₀ values differed between FIPV and SARS-CoV, indicating considerable differences in species specificity. No in vivo studies on any of these FCoV inhibitory compounds have been reported to date. Indomethacin has recently been found to have a potent inhibitory effect on replication of both SARS coronavirus and CCV, but no studies were done on feline coronaviruses by this group.²²¹ However, an earlier study found indomethacin to be ineffective against FIPV.²¹⁸

The incidence of FIP within catteries can be decreased by proper management.²²² Mortality tends to increase as the population of animals, especially kittens, increases. The effect of overcrowding on FIP incidence has been particularly evident in animal shelters. The losses caused by FIP inevitably increase when shelters are overwhelmed with cats, usually

during kitten season, and decrease when overcrowding is controlled; longer shelter stays compound the situation (K Hurley, UC Davis, unpublished information, 2008). Losses from FIP are also proportional to the severity of other kittenhood diseases, including those caused by herpesvirus, calicivirus, chlamydia, mycoplasma, dermatophytes, and numerous other bacterial, viral, fungal, protozoal, and parasitic skin, upper respiratory and enteric infections. Kittens kept in crowded catteries or shelters with a large number of other young animals suffer greatly from concurrent diseases. These diseases stress the kittens' immune system and cause a decrease in growth rate and an increase in susceptibility to disease in general. FeLV infection, a bane of many catteries, shelters and other multi-cat environments in the past, was once the single most powerful potentiator of FIP in cats. Fortunately, FeLV infection has been pushed back into nature in most westernized countries by an aggressive campaign of testing, eradication/isolation of shedders and vaccination, and is no longer a problem in most multi-cat environments.²⁶ Genetics also play an important role in FIP. Genetic resistance/susceptibility factors also affect FIP incidence and obviously have their strongest influence in catteries. Death losses from FIP can sometimes be traced to certain breedings, and further breeding of pairs that produced affected kittens should be avoided. Toms that produce litters that suffer from FIP should be especially avoided, because a given male affects far more litters and individuals than a queen.⁵² Breeding practices in catteries often result in an abundance of younger breeding animals. The incidence of FIP in a static multi-cat household is known to decrease over 3 years.⁴⁴ This may be associated with age resistance to chronic or intermittent FECV shedding; an immunity of sorts develops over a period of many months or years.²⁵ Age resistance over this period of time is seen with several chronic type infections, such as herpesvirus, feline calicivirus FeLV and ringworm. This is why catteries or shelters that keep mainly older cats have much less infectious disease problems than catteries with younger breeding or sheltered animals.

The practice of isolating queens and early weaning of kittens has been advocated for the control of FIP in catteries^{79,260} and is widely practiced. Cattery kittens are not infected with FECV until around 9–10 weeks of age.²⁵ If queens are isolated just prior to parturition, kept in strict quarantine from other sources of FECV exposure, removed from their kittens at the earliest possible time (4–6 weeks after birth), and kittens maintained thereafter in isolation, it is possible to prevent kittens from becoming infected with FECV and hence prevent FIP. However, this practice works best on small catteries and requires very elaborate quarantine facilities and strict control of exposure. Gross and microscopic litter dust contains high levels of virus. Such litter dust is omnipresent and easily spread through the air, caging, pans, accessories and on clothing. Therefore, strict quarantine involves separate quarters and care givers,

separate litter, food and water pans, separate air space, and change-in/change-out protective clothing including shoes/shoe covers/boots, foot baths, etc. Isolation facilities cannot consist of just another room in a home, with no other special precautions. If specifically designed isolation rooms are not available, an alternative would be to transfer kittens at early weaning to distant facilities (or homes) devoid of other cats. The problems with the 'isolation of pregnant queens and early weaning program' are several fold. First, the level of quarantine required to prevent contamination requires expensive facilities and great costs to operate them. Second, what should be done with coronavirus free kittens once they are produced? Infection with coronavirus is almost assured once these kittens are reintroduced into the normal environment and expected to carry out normal activities, such as relocation to new homes, showing and breeding. However, there remains one advantage of a successful isolation and early weaning program, and that is to delay infection until after the kittens are 16 weeks of age or older. This is a time when the immune system began to attain adult levels of activity and when kittens become more resistant to clinical disease of all sorts, including FIP.

Catteries that undertake isolation and early weaning programs should determine whether it is working given their facilities and level of husbandry. If kittens coming out an early weaning program are found to be seropositive at 16 weeks of age and/or shedding FECV from their feces, the program has failed. Given costs and logistical problems, this author does not highly recommend isolation and early weaning programs, especially for larger catteries (over six breeding cats). The most cost-effective means to control FIP losses are fivefold: (1) eliminate overcrowding, and if possible, maintain no more than six breeding animals; (2) maintain a larger proportion of older cats (3 years of age and older); (3) manage feces to mouth spread by properly managing litter boxes, litter replacement, and gross and microscopic spread of litter and litter dust; (4) be highly selective in the breeding program and produce a minimum number of litters, and (5) control genetics by not using any tom (at a minimum) that has produced kittens that have developed FIP, or preferably, use neither toms nor queens that have produced kittens that died from FIP. These steps are far more effective than improperly conducted isolation and early weaning programs and can be easily implemented.

Infection and immunity

Immunity to FIPV infection is a fascinating topic for two reasons. First, it appears that humoral immunity is not important in protection, but may actually participate in the disease process. Second, protective immunity appears to be largely cell mediated and may be of an infection or premonition type. Third, the type and strength of immunity appears to determine the form that FIPV infection will take. It is reasonable to

assume that strong humoral immunity with very weak or non-existent cellular immunity will lead to effusive FIP, humoral immunity with intermediate cellular immunity will manifest as non-effusive FIP, and humoral immunity with strong cellular immunity will prevent the disease. Although these are mainly working hypotheses, there is considerable evidence for each.

Antibodies to FIPV antigens participate in two different immune processes, neither of which correlates with immunity. The first process is an Arthus-type hypersensitivity reaction centered on small venules, while the second process is an antibody-mediated enhancement of viral uptake and replication by macrophages. All three components of an Arthus-type reaction, antigen, complement, and antibody are present at high levels within lesions, especially in those cats with the effusive FIP (Figs 14, 17, 18). Arthus reactions are characterized by vasculitis, edema, inflammatory-cell migration, and necrosis. Antibody-mediated enhancement of disease was first described by Pederesen and Boyle¹³⁹ and confirmed by Weiss and Scott.¹⁴⁰ They noted that the appearance of antibodies and disease signs were always linked. Seronegative (naïve) cats developed the earliest signs of FIP within 10–16 days or more after experimental infection, and the timing of disease always coincided with appearance of antibodies. Healthy FCov antibody positive (ie, FECV exposed) cats were then challenge-exposed with FIPV; fever and disease signs occurred within 24–72 h, instead of the usual 10–21 days or more. If coronavirus seronegative cats were then passively immunized with FECV induced antibodies in the form of serum or immunoglobulin, they also manifested accelerated disease when challenge-exposed with FIPV. The phenomenon of antibody-mediated enhancement was later confirmed to involve antibodies to specific epitopes on the spike protein; these antibodies also functioned as neutralizing antibodies *in vitro*.^{223,224} Macrophage infection was greatly enhanced *in vitro* by the addition of immune serum.^{225,226} This led to a plausible theory in which antibody and complement coated viral particles were taken up through fc receptors on macrophages by a process of endocytosis.²²⁴ This placed the FIPV in its host cell of choice, and from then on the virus is spread to other places of the body by macrophage migration. Antibody-mediated enhancement of macrophage infection appears to be serotype specific, ie, antibody to serotype II FIPVs only enhance macrophage infection with serotype II FIPVs.²²⁶

The antibody-mediated immunopathogenesis in effusive FIP, and the role of macrophages in disease, appears similar to that described for the Dengue hemorrhagic shock syndrome.^{227–232} The hallmark of Dengue hemorrhagic fever and effusive FIP is an Arthus-type reaction. Viral laden macrophages, viral particles, and viral proteins accumulate around small venules. These localized sources of antigen, as well as antigens in the blood, can react with complement to

form immune complexes. In turn, immune complexes deposit around small venules and trigger the release of specific macrophage factors that cause tissue damage.^{13,135,139,143,144,177,225} Paltrinieri et al¹⁴⁶ also demonstrated that FIP lesions contained many virus-infected macrophages and that extracellular viral antigens were also detectable in the foci along with necrosis. Necrosis is one hallmark of Arthus-type vasculitis.

Although a great deal has been made of antibody-mediated enhancement in FIP, it may not be as important in nature as in the laboratory.⁴⁴ Furthermore, the phenomenon has been described mainly between certain FCoV isolates, such as FIPV-UCD1 and FECV-UCD,¹³⁹ FIPV-UCD1 and unknown FECV strains,¹⁴⁰ and FIPV-UCD8 and FECV-RM.¹⁸³ We have not observed this phenomenon with other field strains of FIPV and FECV-RM (NC Pedersen, UC Davis, personal observation, 2008). In general, it appears that the more virulent the FIPV isolate, the more likely it is to respond to antibody enhancement.

Antibodies to the spike protein may also not always be harmful. Western blot antibody responses against the three major structural proteins have been measured in cats naturally infected with FECV and compared to disease outcome, i.e., recovery, chronic asymptomatic carrier state, or FIP.²³³ The cats with chronic asymptomatic infections developed a spike glycoprotein relative to anti-M glycoprotein antibody response that was at least 30-fold higher than cats with chronic asymptomatic or symptomatic infections. It was concluded that antibodies to the spike protein favored clearance of the virus after natural infection and were not a risk factor for the establishment of a chronic infection.

Although many studies support the special role of antibodies in FIP and in the form it takes, there are relatively few mechanistic studies on actual B-cell responses in FIP. Takano et al²³⁴ demonstrated five factors associated with B-cell activation in FIP. They found that the ratio of peripheral blood sIg(+) CD21(−) B-cells was higher in cats with FIP than in SPF cats; that the albumin-to-globulin ratio has negative correlation with the ratio of peripheral blood sIg(+) CD21(−) B-cell; that cells strongly expressing mRNA of the plasma cell master gene, B-lymphocyte-induced maturation protein 1 (Blimp-1), were increased in peripheral blood in cats with FIP; that mRNA expression of B-cell differentiation/survival factors, IL-6, CD40 ligand, and B-cell-activating factor belonging to the TNF family (BAFF), were enhanced in macrophages in cats with FIP; and that mRNAs of these B-cell differentiation/survival factors were over-expressed in antibody-dependent enhancement (ADE)-induced macrophages. In this scenario, virus-infected macrophages overproduce B-cell differentiation/survival factors, which in turn act to promote B-cell differentiation into plasma cells. This same group²³⁵ also investigated key steps in ADE in FIP such as involvement of the virus receptor and the

requirement for acidification of the endosome for cellular invasion. They concluded that aminiopeptidase N was not required for antibody enhancement. However, acidification of the endosome was necessary for cellular invasion by FIPV, regardless of the presence or absence of antibodies.

If humoral immunity does not protect cats against virulent strains of FIPV, what then is the nature of FIPV immunity? It has been postulated that immunity to FIPV is largely cell mediated.⁸³ Reasons for this assumption include the following: (1) The non-effusive form of FIP resembles tuberculosis and deep mycotic infections of humans and animals, and immunity to these infections is known to involve mainly cellular mechanisms; (2) the lesions of dry FIP resemble type IV hypersensitivity reactions with central macrophages containing relatively small amounts of virus and surrounded by dense infiltrates of plasma cells and CD4+ lymphocytes,²³⁶ while the pyogranulomas of wet FIP are aggregates of macrophages stuffed with virus and surrounded mainly by neutrophils and edema; (3) the clinical incidence of FIP can be increased greatly by concurrent FeLV infection,^{119,121,172,237} and FeLV infection is a potent suppressant of cellular immunity and T-cell mediated humoral immunity²³⁷; (4) immunity to FIP cannot be transferred passively with hyperimmune serum, regardless of whether the serum is taken from FECV-infected cats or cats that survived an FIPV challenge^{83,139}; (5) a delayed-type hypersensitivity reaction to FIP antigens can be evoked in the conjunctiva of FIP immune cats and peripheral blood lymphocytes of recovered cats respond in vitro to FIPV antigen,¹¹⁹ and (6) cats are known to carry FIPV as a latent or sequestered infection, and this infection can be reactivated by infecting such carriers with FeLV, but not with methylprednisolone acetate.¹¹⁹ A carrier state of the latter type is known to exist in infections like tuberculosis, blastomycosis, histoplasmosis, and coccidioidomycosis and immunity is sustained in these situations by the persistence of small numbers of organisms in mesenteric or bronchial lymph nodes. This type of immunity, called premonition or infection immunity, persists only as long as intracellular pathogens persist in a reactivatable form.¹¹⁹ This same phenomenon may have been observed with cats immunized with a virulence modified live FIPV.¹⁹⁷ Immunized cats showed no outward signs of disease when challenge-exposed with virulent FIPV over 4 months later, but residual lesions of FIP were found histologically. Stoddart et al¹⁸⁵ studied virus shedding and immune responses in eight SPF cats inoculated orally or intraperitoneally with cell culture-adapted FIPV. Virus was recovered from both feces and oropharyngeal swabs for approximately 2 weeks after inoculation and before clinical signs of disease developed. All eight cats showed a profound suppression in their peripheral blood lymphocyte blastogenic responses to Con A, which recovered to pre-inoculation levels in only

two of the cats, one of which survived. Both Con A reactive cats also had lymphocyte blastogenic responses to FIPV antigen on the 21st day after infection, with the greatest response being in the survivor. Cats dying of FIP after 16–18 days developed no response to FIPV antigen. Antibody titers, measured by immunofluorescence and by virus neutralization, rose rapidly to very high levels in all cats, regardless of the route of inoculation. This study also supported the role of cell mediated immunity, rather than antibodies in FIP.

DeGroot-Mijnes et al²³⁸ put forward a unified concept of T-cell responses in FIP. They postulated that virus-induced T-cell depletion and the antiviral T-cell response are opposing forces and that the efficacy of early T-cell responses critically determines the outcome of the infection. If the virus wins out, FIP will result, while if the host wins out no disease will develop. They observed a consistent rise in the levels of viral RNA in the blood of cats with end-stage FIP, indicating fatal disease is directly related to a loss of immune control and unchecked viral replication. Paltrinieri et al²³⁹ analyzed lymphocyte subsets CD5, CD4, CD8, CD21 markers by flow cytometry. Cats that were recently infected with FECV that did not develop FIP had a transient increase in T-cells. The FECV-infected cats with a high prevalence of FIP had a moderate and persistent decrease in T-cell subsets, while cats with FIP had severe decreases in all lymphocyte subsets. Of course, it can be argued in a chicken or egg manner that it is the level of viremia that determines the outcome.

There are additional studies that support a role for cellular immunity, possibly of the premonition type, in FIP resistance and susceptibility. It is possible to immunize cats against FIPV by starting with small sub-infectious doses of virus and gradually increasing the dose over time.⁸³ Cats immunized in this manner can eventually resist infection with dosages of virus that would be lethal to naïve cats. However, this immunity can be overcome with time and by very large amounts of virulent virus. Moreover, one cat immunized in this manner, and repeatedly immune to over 1000 cat infectious doses of virulent FIPV over 3 or more years eventually succumbed to non-effusive FIP (NC Pedersen, UC Davis, personal observation, 2008). The author also observed a naturally infected cat that responded to non-specific treatment and went into a sustained remission, only to re-develop FIP 2 years later and die. Premonition immunity may also be passed from FIPV immune queens to their kittens.¹¹⁹ Kittens born to such queens frequently showed a typical antibody pattern of both maternal immunoglobulin transfer and maternal infection. Maternal antibodies to FCoV were noted in kitten's blood shortly after birth and declined over the next several weeks, and then spontaneously increased. The first peak of antibodies corresponded to the acquisition and loss of maternal antibodies, while the second peak resulted from an active immune response by the kittens. Five of six kittens that were challenged with FIPV at 8–10 weeks of age resisted FIPV-UCD1

challenge-exposure, while 3/5 of these surviving kittens succumbed to an accelerated form of effusive FIP when infected at 22 weeks of age.¹¹⁹ FIP was reactivated by a secondary FeLV infection in almost all cats within the first 2 months after resisting disease from a primary FIPV infection, but not after 4–6 months.¹¹⁹ This situation resembles that seen in latent FeLV infections.²⁴⁰ Latency in FeLV infection is merely an extension of the recovery process and usually resolves within 6 months of the disappearance of viremia. This appears to be characteristic of many infectious diseases in which cellular immunity is important for recovery; the longer the period after recovery, the more difficult it is to demonstrate persistence of the agent. Immunity to many infections, including FIP, must be a slow, ongoing process that takes weeks, months or years. In some individuals, the agent may persist for a lifetime.

Several studies of FIP have attempted to link the occurrence of disease to certain Th1 profiles of cytokine expression. Kiss et al,¹⁸³ in a small pilot type study, suggested that cats that developed either wet or dry FIP after experimental infection expressed high levels of mRNA for TNF- α and low levels of mRNA for interferon gamma, while cats that resisted disease had the opposite response. The negative role of TNF- α in FIP was supported by studies that linked TNF- α released from macrophages to apoptosis of CD4+ and CD8+ T-cells and the resultant lymphopenia.²⁴¹ The TNF- α may also upregulate the feline aminopeptidase-N receptor in feline macrophages,²⁴² making them more susceptible to infection. A similar type study on wet FIP measured the cellular expression of interferon gamma by various types of lesional inflammatory cells.²⁴³ Cells within lesions included B-cells and plasma cells as well as CD4+ and CD8+ T-cells. However, the macrophage seemed to be the key cellular element in both wet and dry forms of FIP. Interferon-gamma expression was up-regulated within macrophages in the inflammatory lesions suggesting a local activation. Dean et al²⁴⁴ attempted to correlate histologic changes in lymphoid tissues, such as lymphoid hyperplasia, lymphoid depletion, histiocytosis, and granuloma formation, with cytokine expression. Viral RNA was found in 76% of mediastinal lymph nodes, spleen and mesenteric lymph node as compared to 27% of popliteal lymph node, cervical lymph node and femoral bone marrow. All tissues positive for virus replication also demonstrated lymphoid depletion. Affected tissues had lower levels of IL-4 and IL-12-p40 mRNA and higher levels of IL-10 mRNA, but no differences in IFN- γ or TNF- α mRNA. The TNF- α protein expression was greater in affected tissues and associated with a shift in the source of TNF- α from macrophages to lymphocytes. Therefore, FIPV replication, lymphocyte depletion in tissues, and alterations in cytokine transcription and translation were co-localized to the same tissues. A possible role for TNF- α in the previously described FIPV-induced lymphocyte apoptosis was also suggested. Cytokine responses have been compared between cats with

neurological (focal) or generalized FIP, on the rationale that localized neurologic disease is more homogeneous, ie, stereotypic, than generalized FIP.²⁴⁵ IL-1 β , IL-6, IL-12, IL-18, TNF- α , macrophage inhibitory protein (MIP)-1 α , and RANTES showed no up-regulation in the brains of control cats, moderate up-regulation in cats with neurologic FIP, and high up-regulation in cats with generalized FIP. IFN- γ gene transcription was upregulated in cats with generalized FIP and slightly down-regulated in cats with neurologic FIP; variance was high in cats with generalized FIP and much lower in cats with neurologic FIP. A large component of the variance (91.7%) was accounted for by IL-6, MIP-1 α , and RANTES levels.

In another cytokine study, a group of 8-week-old kittens were pre-immunized with two recombinant FIPV spike proteins and then challenged intranasally with FIPV-79-1146.²⁴⁶ All of the kittens developed confirmed FIP. The recombinant proteins induced little or no specific antibody response prior to challenge and failed to enhance or inhibit the course of disease compared to controls. Mitogen stimulated PBMCs collected after 1 week showed small increases in the expression of IL-6 and interferon-gamma mRNA, which correlated with an initial febrile response. Thereafter, the expression of IL-6 mRNA remained unaltered until signs of FIP developed. At this point, mRNA levels of IL-2, IL-4, IL-10, IL-12 and interferon gamma were markedly depressed.

Kipar et al⁵¹ compared cytokine mRNA levels in various lymphoid tissues of cats with exposure to FECV, with or without developing FIP. They noted that lymphoid tissues were normal or hyperplastic in healthy FECV exposed cats, but that both B- and T-cell depletion was present in cats that developed FIP. Therefore, they compared functional changes in bone marrow and mesenteric lymph nodes in healthy FECV exposed cats and cats that developed FIP. The FECV-infected cats that did not develop FIP exhibited significantly higher IL-10 levels in the spleen and significantly lower levels of IL-6, G- and M-CSF in mesenteric lymph nodes. In contrast, IL-12-p40 levels were significantly lower in lymphatic tissues in cats with FIP compared to FECV-infected cats without FIP. Cats with FIP had significantly higher IL-1 β levels and lower TNF- α levels in mesenteric lymph nodes and lower M-CSF levels in the spleen. They concluded that FECV exposed cats that do not develop FIP are able to make protective immunity and avoid excessive macrophage activation and FIP, possibly by up-regulation of IL-10. The development of FIP may also be associated with a lack of IL-12 production, which inhibits an effective cellular immune response and allows for monocyte/macrophage activation. Rapid activation of the p38 MAPK pathway has been demonstrated in FIPV infected blood mononuclear cells from SPF cats.²⁴⁷ The MAPK activation led to the production of pro-inflammatory cytokines such as TNF- α and IL-1 β . The TNF- α production was inhibited by pyridinyl imidazole inhibitors.

Recent studies also measured the concentration of interferon gamma in FECV exposed cats that developed

FIP.⁴⁹ They found that healthy FECV exposed cats living in catteries with a high incidence of FIP had the highest serum interferon-gamma concentrations. However, serum concentrations of interferon gamma were not significantly different in cats that developed FIP than in healthy FECV exposed cats in catteries with a low prevalence of FIP. The concentration of interferon gamma was significantly higher in the effusions than in the serum of cats with FIP, probably due to interferon-gamma production within lesions. A similar study measured cytokine mRNA²⁴⁸; when compared with SPF cats, cytokine production was upregulated in non-symptomatic FECV exposed cats in catteries with no FIP. The appearance FIP in the cattery was associated with an increased expression of cytokines, in particular there was an increased production of IL-1 β and interferon gamma, suggesting that these cytokines helped protect against FIP. This hypothesis was supported by the low levels of interferon gamma recorded in blood from cats with FIP. The most compelling corroborative evidence for the role of interferon gamma in protection against FIP in cats comes from interferon-gamma gene knockout mice. Kyuwa et al^{65,66} described granulomatous peritonitis and pleuritis virtually identical to that of FIP in knockout mice infected with a laboratory strain of mouse hepatitis virus (a murine coronavirus). An identical disease was observed in this same strain of knockout mice that were naturally exposed to a field strain of murine coronavirus.⁶⁴

Both genetic⁵² and host²⁸ factors appear to have a strong influence on resistance of susceptibility to FIPV in nature. Studies of FIP in a number of purebred Persian catteries showed that susceptibility is heritable and accounts for about 50% of the disease incidence.⁵² Addie et al⁴⁸ attempted to link disease susceptibility to certain alleles within the DRB gene of the feline MHC (feline leucocyte antigen or FLA). Individual cats were shown to have between two and six FLA-DRB alleles, but no specific allele appeared to be associated with either the development of FIP, resistance to FCoV in general, or to FECV carrier status. However, this was only a pilot study and lacked the numbers of cats or breadth of study to conclude that genetic differences within the FLA complex are not involved in FIP. Kipar et al²⁴⁹ reported that cats that developed FIP after natural FCoV exposure had a significantly higher rate of viral replication or a reduced capacity for virus clearance than cats that were exposed but did not develop FIP, suggesting a host factor.

The FeLV is a potent potentiator of FIP. Thirty-five cases of FIP were observed among 500 conventional (non-SPF except for FeLV) cats that had been experimentally infected with FeLV by natural contact or experimental infection.^{119,121} Deaths due to FIP occurred within a relatively short time after they became FeLV viremic, and only one cat in a similar cohort of non-FeLV exposed cats died of FIP. Antibody titers to FIPV began to raise progressively after the cats became viremic for FeLV and reached high levels prior to death from FIP.¹¹⁹

Animal and public health considerations

FIPV is a naturally occurring infection of domestic and wild Felidae. People are not hosts for the virus. Dogs and swine can be experimentally infected with FIPV. One of the first commercial CCV vaccines for dogs may have actually consisted of FIPV; hundreds of dogs died of severe neurologic and pancreatic disease before it was recalled.²⁵⁰ A mild to moderately severe TGE-like syndrome occurs in baby pigs.²⁵¹ However, it is doubtful that FIPV is a cause of naturally occurring disease in these species.

The comparison of feline coronaviruses, in particular FIPV, and the human SARS coronavirus is noteworthy. The coronavirus found in Palm civet cats (a mustelidae and not a felidae) has over 99% homology to the human SARS coronavirus, and is apparently well adapted to its host species.²⁵² However, this virus was able to genetically adapt to humans²⁵² with effects that were potentially devastating. A coronavirus with 92% or more homology to the SARS coronavirus exists in the horseshoe bat,^{252,253} suggesting that coronaviruses have adapted species by species over relatively short to long periods of time. This ability to mutate through recombination, insertion/deletion mutations, and single nucleotide polymorphisms and change host species is reminiscent of the close relationships between canine, porcine and feline coronaviruses.^{7,14,18–23} The human SARS coronavirus also has an interesting 29 nucleotide deletion in one of its accessory genes (ORF 8a) that is not present in its host species.²⁵⁴ Damaging mutations within an accessory gene of FECV (ORF 3c) are known to be associated with the FECV → FIPV mutation in cats.²⁹ The participation of both host and virus factors are important for the development of SARS in a rat model, with increased virulence in old compared to young rats, as in humans.²⁵⁵ Both host and virus factors are involved in FIP in cats. Diseases closely resembling FIP of cats, and caused by species related coronaviruses, have been described in both ferrets,^{256–258} and mice.^{64–66}

References

- Holzworth JE. Some important disorders of cats. *Cornell Vet* 1963; **53**: 157–60.
- Feldman BF, Jortner BS. Clinico-pathology conference. *J Am Vet Med Assoc* 1965; **144**: 1409–11.
- Wolfe LG, Griesemer RA. Feline infectious peritonitis. *Pathol Vet* 1966; **3**: 255–70.
- Zook BC, King NW, Robinson RL, McCombs HL. Ultrastructural evidence for the viral etiology of feline infectious peritonitis. *Pathol Vet* 1968; **5**: 91–5.
- Ward J. Morphogenesis of a virus in cats with experimental feline infectious peritonitis. *Virology* 1970; **41**: 191–4.
- Montali RJ, Strandberg JD. Extraperitoneal lesions in feline infectious peritonitis. *Vet Pathol* 1972; **9**: 109–21.
- Pedersen NC, Ward J, Mengeling WL. Antigenic relationship of the feline infectious peritonitis virus to coronaviruses of other species. *Arch Virol* 1978; **58**: 45–53.
- Pedersen NC. Morphologic and physical characteristics of feline infectious peritonitis virus and its growth in autochthonous peritoneal cell cultures. *Am J Vet Res* 1976; **37**: 567–72.
- O'Reilly KJ, Fishman B, Hitchcock LM. Feline infectious peritonitis: isolation of a coronavirus. *Vet Rec* 1979; **104**: 348.
- Black JW. Recovery and in vitro cultivation of a coronavirus from laboratory-induced cases of feline infectious peritonitis (FIP). *Vet Med Small Anim Clin* 1980; **75**: 811–4.
- Hoshino Y, Scott FW. Immunofluorescent and electron microscopic studies of feline small intestine organ cultures infected with feline infectious peritonitis virus. *Am J Vet Res* 1980; **41**: 672–81.
- Pedersen NC, Boyle JF, Floyd K. Infection studies in kittens utilizing feline infectious peritonitis virus propagated in cell culture. *Am J Vet Res* 1981; **42**: 363–7.
- Jacobse-Geels HE, Horzinek MC. Expression of feline infectious peritonitis coronavirus antigens on the surface of feline macrophage-like cells. *J Gen Virol* 1983; **64**: 1859–66.
- Pedersen NC, Black JW, Boyle JF, Evermann JF, McKeirnan AJ, Ott RL. Pathogenic differences between various feline coronavirus isolates. Coronaviruses; molecular biology and pathogenesis. *Adv Exp Med Biol* 1984; **173**: 365–80.
- Pedersen NC. Feline infectious peritonitis. Something old, something new. *Feline Pract* 1976; **6**: 42–51.
- Jakob H. Therapeutische, kasuistische und statistische Mitteilungen aus der Klinik für kleine Haustiere an der Reichstierarzneischule in Utrecht (Holland), Jahrgang 1912/13. *Z Tiermed Microbiol Immunol* 1914; **18**: 193.
- de Groot RJ, Horzinek MC. Feline infectious peritonitis. In: Siddell SG, ed. *The Coronaviridae: a review of coronaviruses and toroviruses*. New York and London: Plenum Press, 1995: 294.
- Haelterman EO. Epidemiological studies of transmissible gastroenteritis of swine. *US Livestock Sanitation Assoc Proc* 1962; **66**: 305–15.
- Motokawa K, Hohdatsu T, Hashimoto H, Koyama H. Comparison of the amino acid sequence and phylogenetic analysis of the peplomer, integral membrane and nucleocapsid proteins of feline, canine and porcine coronaviruses. *Microbiol Immunol* 1996; **40**: 425–33.
- Benetka V, Kolodziejek J, Walk K, Rennhofer M, Möstl K. M gene analysis of atypical strains of feline and canine coronavirus circulating in an Austrian animal shelter. *Vet Rec* 2006; **159**: 170–4.
- Herrewegh AA, Smeenk I, Horzinek MC, Rottier PJ, de Groot RJ. Feline coronavirus type II strains 79-1683 and 79-1146 originate from a double recombination between feline coronavirus type I and canine coronavirus. *J Virol* 1998; **72**: 4508–14.
- Wesley RD. The S gene of canine coronavirus, UCD-1, is more closely related to the S gene of transmissible gastroenteritis virus than to that of feline infectious peritonitis virus. *Virus Res* 1999; **61**: 145–52.
- McArdle F, Bennett M, Gaskell RM, Tennant B, Kelly DF, Gaskell CJ. Induction and enhancement of feline infectious peritonitis by canine coronavirus. *Am J Vet Res* 1992; **53**: 1500–6.
- de Groot RJ, ter Haar RJ, Horzinek MC, van der Zeijst BA. Intracellular RNAs of the feline infectious peritonitis strain 79-1146. *J Gen Virol* 1987; **68**: 995–1002.

25. Pedersen NC, Allen CE, Lyons LA. Pathogenesis of feline enteric coronavirus infection. *J Feline Med Surg* 2008; **10**: 529–41.
26. Weijer K, UijtdeHaag F, Osterhaus A. Control of feline leukaemia virus by a removal programme. *Vet Rec* 1986; **119**: 555–6.
27. Pedersen NC, Boyle JF, Floyd K, Fudge A, Barker J. An enteric coronavirus infection of cats and its relationship to feline infectious peritonitis. *Am J Vet Res* 1981; **42**: 368–77.
28. Poland AM, Vennema H, Foley JE, Pedersen NC. Two related strains of feline infectious peritonitis virus isolated from immunocompromised cats infected with a feline enteric coronavirus. *J Clin Microbiol* 1996; **34**: 3180–4.
29. Vennema H, Poland A, Foley J, Pedersen NC. Feline infectious peritonitis viruses arise by mutation from endemic feline enteric coronaviruses. *Virology* 1998; **243**: 150–7.
30. Pedersen NC, Johnson L, Theilen GH. Biological behavior of tumors and associated retroviremia in cats inoculated with Snyder–Theilen fibrosarcoma virus and the phenomenon of tumor recurrence after primary regression. *Infect Immun* 1984; **43**: 631–6.
31. Hardy Jr WD, Hurvitz AI. Feline infectious peritonitis: experimental studies. *J Am Vet Med Assoc* 1971; **158**: 994–1002.
32. Kennedy M, Boedeker N, Gibbs P, Kania S. Deletions in the 7a ORF of feline coronavirus associated with an epidemic of feline infectious peritonitis. *Vet Microbiol* 2001; **81**: 227–34.
33. Lin CN, Su BL, Huang HP, Lee JJ, Hsieh MW, Chueh LL. Field strain feline coronaviruses with small deletions in ORF7b associated with both enteric infection and feline infectious peritonitis. *J Feline Med Surg*. [Epub ahead of print].
34. Shiba N, Maeda K, Kato H, Mochizuki M, Iwata H. Differentiation of feline coronavirus type I and II infections by virus neutralization test. *Vet Microbiol* 2007; **124**: 348–52.
35. Fiscus SA, Teramoto YA. Antigenic comparison of feline coronavirus isolates: evidence for markedly different peplomer glycoproteins. *J Virol* 1987; **6**: 2607–13.
36. Benetka V, Kübber-Heiss A, Kolodziejek J, Nowotny N, Hofmann-Parisot M, Möstl K. Prevalence of feline coronavirus types I and II in cats with histopathologically verified feline infectious peritonitis. *Vet Microbiol* 2004; **99**: 31–42.
37. Kummrow M, Meli ML, Haessig M, et al. Feline coronavirus serotypes 1 and 2: seroprevalence and association with disease in Switzerland. *Clin Diagn Lab Immunol* 2005; **12**: 1209–15.
38. Hohdatsu T, Okada S, Ishizuka Y, Yamada H, Koyama H. The prevalence of types I and II feline coronavirus infections in cats. *J Vet Med Sci* 1992; **54**: 557–62.
39. Herrewegh AA, Vennema H, Horzinek MC, Rottier PJ, de Groot RJ. The molecular genetics of feline coronaviruses: comparative sequence analysis of the ORF7a/7b transcription unit of different biotypes. *Virology* 1995; **212**: 622–31.
40. Pedersen NC, Meric SM, Ho E, Johnson L, Plucker S, Theilen GH. The clinical significance of latent feline leukemia virus infection in cats. *Feline Pract* 1984; **14**: 32–48.
41. Dewerchin HL, Cornelissen E, Nauwynck HJ. Replication of feline coronaviruses in peripheral blood monocytes. *Arch Virol* 2005; **150**: 2483–500.
42. Rottier PJ, Nakamura K, Schellen P, Volders H, Haijema BJ. Acquisition of macrophage tropism during the pathogenesis of feline infectious peritonitis is determined by mutations in the feline coronavirus spike protein. *J Virol* 2005; **79**: 14122–30.
43. Meli M, Kipar A, Müller C, et al. High viral loads despite absence of clinical and pathological findings in cats experimentally infected with feline coronavirus (FCoV) type I and in naturally FCoV-infected cats. *J Feline Med Surg* 2004; **6**: 69–81.
44. Addie DD, Toth S, Murray GD, Jarrett O. Risk of feline infectious peritonitis in cats naturally infected with feline coronavirus. *Am J Vet Res* 1995; **56**: 429–34.
45. Dye C, Siddell SG. Genomic RNA sequence of feline coronavirus strain FCoV C1Je. *J Feline Med Surg* 2007; **9**: 202–13.
46. Addie DD, Toth S, Herrewegh AA, Jarrett O. Feline coronavirus in the intestinal contents of cats with feline infectious peritonitis. *Vet Rec* 1996; **139**: 522–3.
47. Herrewegh AA, Mähler M, Hedrich HJ, et al. Persistence and evolution of feline coronavirus in a closed cat-breeding colony. *Virology* 1997; **4**: 349–63.
48. Addie DD, Kennedy LJ, Ryvar R, et al. Feline leucocyte antigen class II polymorphism and susceptibility to feline infectious peritonitis. *J Feline Med Surg* 2004; **6**: 59–62.
49. Giordano A, Paltrinieri S. Interferon-gamma in the serum and effusions of cats with feline coronavirus infection. *Vet J* 2008; **10**: [Epub ahead of print].
50. Paltrinieri S, Gelain ME, Cecilian F, Ribera AM, Battilani M. Association between faecal shedding of feline coronavirus and serum alpha1-acid glycoprotein sialylation. *J Feline Med Surg* 2008; **10**: 514–8.
51. Kipar A, Meli ML, Failing K, et al. Natural feline coronavirus infection: differences in cytokine patterns in association with the outcome of infection. *Vet Immunol Immunopathol* 2006; **112**: 141–55.
52. Foley JE, Pedersen NC. Inheritance of susceptibility of feline infectious peritonitis in purebred catteries. *Feline Pract* 1996; **24**: 14–22.
53. Foley JE, Poland A, Carlson J, Pedersen NC. Risk factors for feline infectious peritonitis among cats in multiple-cat environments with endemic feline enteric coronavirus. *J Am Vet Med Assoc* 1997; **210**: 1313–8.
54. Colby ED, Low RJ. Feline infectious peritonitis. *Vet Med Small Anim Clin* 1970; **65**: 783–6.
55. Colly LP. Feline infectious peritonitis. *Vet Clin North Am* 1973; **3**: 34.
56. Fowler ME. Zoo and wild animal medicine. Philadelphia: WB Saunders, 1978: 660.
57. Juan-Sallés C, Domingo M, Herráez P, Fernández A, Segalés J, Fernández J. Feline infectious peritonitis in servals (*Felis serval*). *Vet Rec* 1998; **143**: 535–6.
58. Pedersen NC. Feline infectious peritonitis and feline enteric coronavirus infections. Part I: feline enteric coronavirus. *Feline Pract* 1983; **13**: 13–9.
59. Pfeifer ML, Evermann JF, Roelke ME, Gallina AM, Ott RL, McKeirnan AJ. Feline infectious peritonitis in a captive cheetah. *J Am Vet Med Assoc* 1983; **183**: 1317–9.
60. Poelma FG, Peters JC, Mieog WHW, Zwart P. Infectious Peritonitis bei Karakal (*Felis caracal*) and Nordluchs (*Felis lynx lynx*). Proceedings Erkrankungen der Zootiere, 13th International Symposium of Zoo Veterinarians; Helsinki, Finland, 1974: 249–53.
61. Theobald J. In: Fowler ME, ed. Zoo and wild animal medicine. Philadelphia: WB Saunders, 1978: 650–67.

62. Tuch K, Witte KH, Wüller H. Feststellung der feline infektiösen Peritonitis (FIP) bei Hauskatzen und Leoparden in Deutschland. *Zentralblatt Veterinärmed B* 1974; **21**: 426–41.
63. Watt NJ, MacIntyre NJ, McOrist S. An extended outbreak of infectious peritonitis in a closed colony of European wildcats (*Felis sylvestris*). *J Comp Pathol* 1993; **108**: 73–9.
64. France MP, Smith AL, Stevenson R, Barthold SW. Granulomatous peritonitis and pleuritis in interferon-gamma gene knockout mice naturally infected with mouse hepatitis virus. *Aust Vet J* 1999; **77**: 600–4.
65. Kyuwa S, Tagawa Y, Machii K, et al. MHV-induced fatal peritonitis in mice lacking IFN-gamma. *Adv Exp Med Biol* 1988; **440**: 445–50.
66. Kyuwa S, Tagawa Y, Shibata S, Doi K, Machii K, Iwakura Y. Murine coronavirus-induced subacute fatal peritonitis in C57BL/6 mice deficient in gamma interferon. *J Virol* 1998; **72**: 9286–90.
67. Martínez J, Reinacher M, Perpiñán D, Ramis A. Identification of group 1 coronavirus antigen in multisystemic granulomatous lesions in ferrets (*Mustela putorius furo*). *J Comp Pathol* 2008; **138**: 54–8.
68. Pedersen NC. Feline infectious peritonitis and feline enteric coronavirus infections. Part II: feline infectious peritonitis. *Feline Pract* 1983; **13**: 5–19.
69. Foley JE, Poland A, Carlson J, Pedersen NC. Patterns of feline coronavirus infection and fecal shedding from cats in multiple-cat environments. *J Am Vet Med Assoc* 1997; **210**: 1307–12.
70. Pedersen NC, Sato R, Foley JE, Poland AM. Common virus infections in cats, before and after being placed in shelters, with emphasis on feline enteric coronavirus. *J Feline Med Surg* 2004; **6**: 83–8.
71. Bell ET, Toribio JA, White JD, Malik R, Norris JM. Seroprevalence study of feline coronavirus in owned and feral cats in Sydney, Australia. *Aust Vet J* 2006; **84**: 74–81.
72. Bell ET, Malik R, Norris JM. The relationship between the feline coronavirus antibody titre and the age, breed, gender and health status of Australian cats. *Aust Vet J* 2006; **84**: 2–7.
73. Addie DD, Jarrett O. Use of a reverse-transcriptase polymerase chain reaction for monitoring the shedding of feline coronavirus by healthy cats. *Vet Rec* 2001; **148**: 649–53.
74. Foley JE, Poland A, Carlson J, Pedersen NC. Patterns of feline coronavirus infection and fecal shedding from cats in multiple-cat households. *J Am Vet Med Assoc* 1997; **210**: 1307–12.
75. Marioni-Henry K, Vite CH, Newton AL, Van Winkle TJ. Prevalence of diseases of the spinal cord of cats. *J Vet Intern Med* 2004; **18**: 851–8.
76. Rohrbach BW, Legendre AM, Baldwin CA, Lein DH, Reed WM, Wilson RB. Epidemiology of feline infectious peritonitis among cats examined at veterinary medical teaching hospitals. *J Am Vet Med Assoc* 2001; **218**: 1111–5.
77. Cave TA, Thompson H, Reid SW, Hodgson DR, Addie DD. Kitten mortality in the United Kingdom: a retrospective analysis of 274 histopathological examinations (1986 to 2000). *Vet Rec* 2002; **151**: 497–501.
78. Potkay S, Bacher JD, Pitts TW. Feline infectious peritonitis in a closed breeding colony. *Lab Anim Sci* 1974; **24**: 279–89.
79. Addie DD, Jarrett O. Control of feline coronavirus in breeding catteries by serotesting, isolation, and early weaning. *Feline Pract* 1995; **23**(3): 92–5.
80. Norris JM, Bosward KL, White JD, Baral RM, Catt MJ, Malik R. Clinicopathological findings associated with feline infectious peritonitis in Sydney, Australia: 42 cases (1990–2002). *Aust Vet J* 2005; **83**: 666–73.
81. Pesteau-Somogyi LD, Radzai C, Pressler BM. Prevalence of feline infectious peritonitis in specific cat breeds. *J Feline Med Surg* 2006; **8**: 1–5.
82. Evermann JF, Baumgartner L, Ott RL, Davis EV, McKiernan AJ. Characterization of a feline infectious peritonitis virus isolate. *Vet Path* 1981; **18**: 256–65.
83. Pedersen NC, Black JW. Attempted immunization of cats against feline infectious peritonitis using either avirulent live virus or sublethal amounts of virulent virus. *Am J Vet Res* 1983; **44**: 229–34.
84. Pedersen NC, Floyd K. Experimental studies with three new strains of feline infectious peritonitis virus FIPV-UCD2, FIPV-UCD3, and FIPV-UCD4. *Compend Cont Educ Pract Vet* 1985; **7**: 1001–11.
85. Wright KN, Gompf RE, DeNovo Jr RC. Peritoneal effusion in cats: 65 cases (1981–1997). *J Am Vet Med Assoc* 1999; **214**: 375–81.
86. Trotman TK, Mauldin E, Hoffmann V, Del Piero F, Hess RS. Skin fragility syndrome in a cat with feline infectious peritonitis and hepatic lipidosis. *Vet Dermatol* 2007; **18**: 365–9.
87. McKiernan AJ, Evermann JF, Hargis A, Ott RL. Isolation of feline coronaviruses from two cats with diverse disease manifestations. *Feline Pract* 1981; **11**(6): 16–20.
88. Harvey CJ, Lopez JW, Hendrick MJ. An uncommon intestinal manifestation of feline infectious peritonitis: 26 cases (1986–1993). *J Am Vet Med Assoc* 1996; **15**: 1117–20.
89. Van Kruiningen. The classification of feline colitis. *J Comp Pathol* 1983; **93**: 275–94.
90. deMadron E. Pericarditis with cardiac tamponade secondary to feline infectious peritonitis in a cat. *J Am Anim Hosp Assoc* 1986; **22**: 65–9.
91. Bradshaw JM, Pearson GR, Gruffydd-Jones TJ. A retrospective study of 286 cases of neurological disorders of the cat. *J Comp Pathol* 2004; **131**: 112–20.
92. Foley JE, Lapointe JM, Koblik P, Poland A, Pedersen NC. Diagnostic features of clinical neurologic feline infectious peritonitis. *J Vet Intern Med* 1998; **12**: 415–23.
93. Holliday TA. Clinical aspects of some encephalopathies of domestic cats. *Vet Clin North Am Small Anim Clin* 1971; **1**: 367–78.
94. Kornegay JN. Feline infectious peritonitis. *J Am Anim Hosp Assoc* 1978; **14**: 580–4.
95. Legendre AM, Whitenack DL. Feline infectious peritonitis with spinal cord involvement in two cats. *J Am Vet Med Assoc* 1975; **167**: 931–2.
96. Slausen DO, Finn JP. Meningoencephalitis and panophthalmitis in feline infectious peritonitis. *J Am Vet Med Assoc* 1972; **160**: 729–34.
97. Quesnel AD, Parent JM, McDonnell W, Percy D, Lumsden JH. Diagnostic evaluation of cats with seizure disorders: 30 cases (1991–1993). *J Am Vet Med Assoc* 1997; **210**: 65–71.
98. Timmann D, Cizinauskas S, Tomek A, Doherr M, Van de Velde M, Jaggy A. Retrospective analysis of seizures associated with feline infectious peritonitis in cats. *J Feline Med Surg* 2008; **10**: 9–15.

99. Fankhauser R, Fatzer R. Meningitis and *Chorioependymitis granulomatosa* der Katze: mögliche Beziehungen zur feline infectiosen Peritonitis (FIP). *Kleintierpraxis* 1977; **22**: 19–22.
100. Hayashi T, Utsumi F, Takahashi R, Fujiwara K. Pathology of non-effusive-type feline infectious peritonitis and experimental transmission. *Jpn J Vet Sci* 1980; **42**: 197–210.
101. Krum S, Johnson K, Wilson J. Hydrocephalus associated with the noneffusive form of feline infectious peritonitis. *J Am Vet Med Assoc* 1975; **167**: 746–8.
102. Campbell LH, Reed C. Ocular signs associated with feline infectious peritonitis in two cats. *Feline Pract* 1975; **5**: 32–5.
103. Campbell LH, Schiessl MM. Ocular manifestations of toxoplasmosis, infectious peritonitis and lymphosarcoma in cats. *Mod Vet Pract* 1978; **59**: 761–4.
104. Doherty MJ. Ocular manifestations of feline infectious peritonitis. *J Am Vet Med Assoc* 1971; **159**: 417–24.
105. Gelatt KM. Iridocyclitis-panophthalmitis associated with feline infectious peritonitis. *Vet Med Small Anim Clin* 1973; **68**: 56–7.
106. Gillespie JH, Scott FW. Feline viral infections. *Adv Vet Sci Comp Med* 1973; **17**: 163–200.
107. Goodhead AD. Uveitis in dogs and cats: guidelines for the practitioner. *J S Afr Vet Assoc* 1996; **67**: 12–9.
108. Peiffer Jr RL, Wilcock BP. Histopathologic study of uveitis in cats: 139 cases (1978–1988). *J Am Vet Med Assoc* 1991; **198**: 135–8.
109. Rota A, Paltrinieri S, Jussich S, Ubertaini G, Appino S. Priapism in a castrated cat associated with feline infectious peritonitis. *J Feline Med Surg* [Epub ahead of print].
110. Foster RA, Caswell JL, Rinkardt N. Chronic fibrinous and necrotic orchitis in a cat. *Can Vet J* 1996; **37**: 681–2.
111. Sigurdardóttir OG, Kolbjørnsen O, Lutz H. Orchitis in a cat associated with coronavirus infection. *J Comp Pathol* 2001; **124**: 219–22.
112. Kitagawa M, Okada M, Sato T, Kanayama K, Sakai T. A feline case of isolated fourth ventricle with syringomyelia suspected to be related with feline infectious peritonitis. *J Vet Med Sci* 2007; **69**: 759–62.
113. Cannon MJ, Silkstone MA, Kipar AM. Cutaneous lesions associated with coronavirus-induced vasculitis in a cat with feline infectious peritonitis and concurrent feline immunodeficiency virus infection. *J Feline Med Surg* 2005; **7**: 233–6.
114. Declercq J, De Bosschere H, Schwarzkopf I, Declercq L. Papular cutaneous lesions in a cat associated with feline infectious peritonitis. *Vet Dermatol* 2008; **19**: 255–8.
115. Kipar A, Koehler K, Bellmann S, Reinacher M. Feline infectious peritonitis presenting as a tumour in the abdominal cavity. *Vet Rec* 1999; **144**: 118–22.
116. Madewell BR, Crow SE, Nickerson TR. Infectious peritonitis in a cat that subsequently developed a myeloproliferative disorder. *J Am Vet Med Assoc* 1978; **172**: 169–72.
117. MacEwen EG, Hurvitz AI. Diagnosis and management of monoclonal gammopathies. *Vet Clin North Am* 1977; **7**: 119–32.
119. Pedersen NC. Virologic and immunologic aspects of feline infectious peritonitis virus infection. *Adv Exp Med Biol* 1987; **218**: 529–50.
120. Cotter SM, Gilmore CE, Rollins C. Multiple cases of feline leukemia and feline infectious peritonitis in a household. *J Am Vet Med Assoc* 1973; **162**: 1054–8.
121. Pedersen NC, Theilen G, Keane MA, et al. Studies of naturally transmitted feline leukemia virus infection. *Am J Vet Res* 1977; **38**: 1523–31.
122. Ward BC, Pedersen NC. Infectious peritonitis in cats. *J Am Vet Med Assoc* 1966; **154**: 26–35.
123. Toomey JM, Carlisle-Nowak MM, Barr SC, et al. Concurrent toxoplasmosis and feline infectious peritonitis in a cat. *J Am Anim Hosp Assoc* 1995; **31**: 425–58.
124. Van Hamme E, Dewerchin HL, Cornelissen E, Verhasselt B, Nauwynck HJ. Clathrin- and caveolae-independent entry of feline infectious peritonitis virus in monocytes depends on dynamin. *J Gen Virol* 2008; **89**: 2147–56.
125. Dewerchin HL, Cornelissen E, Van Hamme E, Smits K, Verhasselt B, Nauwynck HJ. Surface-expressed viral proteins in feline infectious peritonitis virus-infected monocytes are internalized through a clathrin- and caveolae-independent pathway. *J Gen Virol* 2008; **89**: 2731–40.
126. Delmas B, Gelfi J, Sjöström H, Noren O, Laude H. Further characterization of aminopeptidase-N as a receptor for coronaviruses. *Adv Exp Med Biol* 1993; **342**: 293–8.
127. Benbacar L, Kut E, Besnardeau L, Laude H, Delmas B. Interspecies aminopeptidase-N chimeras reveal species-specific receptor recognition by canine coronavirus, feline infectious peritonitis virus, and transmissible gastroenteritis virus. *J Virol* 1997; **71**: 734–7.
128. Kolb AF, Hegyi A, Maile J, Heister A, Hagemann M, Siddell SG. Molecular analysis of the coronavirus-receptor function of aminopeptidase N. *Adv Exp Med Biol* 1998; **440**: 61–7.
129. Hohdatsu T, Izumiya Y, Yokoyama Y, Kida K, Koyama H. Differences in virus receptor for type I and type II feline infectious peritonitis virus. *Arch Virol* 1998; **143**: 839–50.
130. Hegyi A, Kolb AF. Characterization of determinants involved in the feline infectious peritonitis virus receptor function of feline aminopeptidase N. *J Gen Virol* 1998; **79**: 1387–91.
131. Van Hamme E, Dewerchin HL, Cornelissen E, Nauwynck HJ. Attachment and internalization of feline infectious peritonitis virus in feline blood monocytes and Crandell feline kidney cells. *J Gen Virol* 2007; **88**: 2527–32.
132. Herrewegh AA, Vennema H, Horzinek MC, Rottier PJ, de Groot RJ. The molecular genetics of feline coronaviruses: Comparative sequence analysis for the ORF 7a/b transcription unit of different biotypes. *Virology* 1995; **212**: 622–31.
133. Regan AD, Shraybman R, Cohen RD, Whittaker GR. Differential role for low pH and cathepsin-mediated cleavage of the viral spike protein during entry of serotype II feline coronaviruses. *Vet Microbiol* [Epub ahead of print].
134. Can-Sahna K, Soydal Ataseven V, Pinar D, Oğuzoğlu TC. The detection of feline coronaviruses in blood samples from cats by mRNA RT-PCR. *J Feline Med Surg* 2007; **9**: 369–72.
135. Weiss RC, Scott FW. Pathogenesis of feline infectious peritonitis: pathologic changes and immunofluorescence. *Am J Vet Res* 1981; **42**: 2036–48.
136. Battilani M, Coradin T, Scagliarini A, et al. Quasispecies composition and phylogenetic analysis of feline coronaviruses (FCoVs) in naturally infected cats. *FEMS Immunol Med Microbiol* 2003; **39**: 141–7.

137. Poncelet L, Coppens A, Peeters D, Bianchi E, Grant CK, Kadhim H. Detection of antigenic heterogeneity in feline coronavirus nucleocapsid in feline pyogranulomatous meningoencephalitis. *Vet Pathol* 2008; **45**: 140–53.
138. Kiss I, Kecskeméti S, Tanyi J, Klingeborn B, Belák S. Preliminary studies on feline coronavirus distribution in naturally and experimentally infected cats. *Res Vet Sci* 2000; **68**: 237–42.
139. Pedersen NC, Boyle JF. Immunologic phenomena in the effusive form of feline infectious peritonitis. *Am J Vet Res* 1980; **41**: 868–76.
140. Weiss RC, Scott FW. Antibody-mediated enhancement of disease in feline infectious peritonitis: comparisons with dengue hemorrhagic fever. *Comp Immunol Microbiol Infect Dis* 1981; **4**: 175–89.
141. Dewerchin HL, Cornelissen E, Nauwynck HJ. Feline infectious peritonitis virus-infected monocytes internalize viral membrane-bound proteins upon antibody addition. *J Gen Virol* 2006; **87**: 1685–90.
142. Cornelissen E, Dewerchin HL, Van Hamme E, Nauwynck HJ. Absence of surface expression of feline infectious peritonitis virus. *Vet Microbiol* 2007; **121**: 131–7.
143. Jacobse-Geels HEL, Daha MR, Horzinek MC. Antibody immune complexes and complement activity fluctuations in kittens with experimentally induced feline infectious peritonitis. *Am J Vet Res* 1982; **43**: 666–70.
144. Jacobse-Geels HEL, Daha MR, Horzinek MC. Isolation and characterization of feline C3 and evidence for the immune complex pathogenesis of feline infectious peritonitis. *J Immunol* 1980; **125**: 1606–10.
145. Weiss RC, Dodds WJ, Scott FW. Disseminated intravascular coagulation in experimentally induced feline infectious peritonitis. *Am J Vet Res* 1980; **41**: 663–71.
146. Paltrinieri S, Cammarata MP, Cammarata G, Comazzi S. Some aspects of humoral and cellular immunity in naturally occurring feline infectious peritonitis. *Vet Immunol Immunopathol* 1998; **65**: 205–20.
147. Paltrinieri S, Grieco V, Comazzi S, Cammarata Parodi M. Laboratory profiles in cats with different pathological and immunohistochemical findings due to feline infectious peritonitis (FIP). *J Feline Med Surg* 2001; **3**: 149–59.
148. Sparkes AH, Gruffydd-Jones TJ, Harbour DA. Feline infectious peritonitis: a review of clinicopathological changes in 65 cases, and a critical assessment of their diagnostic value. *Vet Rec* 1991; **129**: 209–12.
149. Hirschberger J, Hartmann K, Wilhelm N, Frost J, Lutz H, Kraft W. Clinical symptoms and diagnosis of feline infectious peritonitis. *Tierarztl Prax* 1995; **23**: 92–9.
150. Harvey JW, Gaskin JM. Feline haptoglobin. *Am J Vet Res* 1978; **39**: 549–53.
151. Boettcher IC, Steinberg T, Matiassek K, Greene CE, Hartmann K, Fischer A. Use of anti-coronavirus antibody testing of cerebrospinal fluid for diagnosis of feline infectious peritonitis involving the central nervous system in cats. *J Am Vet Med Assoc* 2007; **230**: 199–205.
152. Paltrinieri S, Parodi MC, Cammarata G. In vivo diagnosis of feline infectious peritonitis by comparison of protein content, cytology, and direct immunofluorescence test on peritoneal and pleural effusions. *J Vet Diagn Invest* 1999; **11**: 358–61.
153. Rand JS, Parent J, Percy D, Jacobs R. Clinical, cerebrospinal fluid, and histological data from twenty-seven cats with primary inflammatory disease of the central nervous system. *Can Vet J* 1994; **35**: 103–10.
154. Singh M, Foster DJ, Child G, Lamb WA. Inflammatory cerebrospinal fluid analysis in cats: clinical diagnosis and outcome. *J Feline Med Surg* 2005; **7**: 77–93.
155. Barlough JE, Adsit JC, Scott FW. The worldwide occurrence of feline infectious peritonitis. *Feline Pract* 1982; **12**(6): 26–30.
156. Pedersen NC. Serologic studies of naturally occurring feline infectious peritonitis. *Am J Vet Res* 1976; **37**: 1449–53.
157. Pratelli A. Comparison of serologic techniques for the detection of antibodies against feline coronaviruses. *J Vet Diagn Invest* 2008; **20**(1): 45–50.
158. Hartmann K, Binder C, Hirschberger J, et al. Comparison of different tests to diagnose feline infectious peritonitis. *J Vet Intern Med* 2003; **17**: 781–90.
159. Kennedy MA, Abd-Elldaim M, Zika SE, Mankin JM, Kania SA. Evaluation of antibodies against feline coronavirus 7b protein for diagnosis of feline infectious peritonitis in cats. *Am J Vet Res* 2008; **69**: 1179–82.
160. Steinberg TA, Boettcher IC, Matiassek K, et al. Use of albumin quotient and IgG index to differentiate blood- vs brain-derived proteins in the cerebrospinal fluid of cats with feline infectious peritonitis. *Vet Clin Pathol* 2008; **37**: 207–16.
161. Simons AF, Vennema H, Rofina JE, et al. A mRNA PCR for the diagnosis of feline infectious peritonitis. *J Virol Methods* 2005; **124**: 111–6.
162. Dye C, Helps CR, Siddell SG. Evaluation of real-time RT-PCR for the quantification of FCov shedding in the faeces of domestic cats. *J Feline Med Surg* 2008; **10**: 167–74.
163. Bence LM, Addie DD, Eckersall PD. An immunoturbidimetric assay for rapid quantitative measurement of feline alpha-1-acid glycoprotein in serum and peritoneal fluid. *Vet Clin Pathol* 2005; **34**: 335–41.
164. Saverio P, Alessia G, Vito T, Stefano S. Critical assessment of the diagnostic value of feline alpha-1-acid glycoprotein for feline infectious peritonitis using the likelihood ratios approach. *J Vet Diagn Invest* 2007; **19**: 266–72.
165. Paltrinieri S, Metzger C, Battilani M, Gelain ME, Giordano A. Serum alpha-1-acid glycoprotein (AGP) concentration in non-symptomatic cats with feline coronavirus (FCov) infection. *J Feline Med Surg* 2007; **9**: 271–7.
166. Duthie S, Eckersall PD, Addie DD, Lawrence CE, Jarrett O. Value of alpha-1-acid glycoprotein in the diagnosis of feline infectious peritonitis. *Vet Rec* 1997; **141**: 299–303.
167. Cecilian F, Grossi C, Giordano A, Pocacqua V, Paltrinieri S. Decreased sialylation of the acute phase protein alpha-1-acid glycoprotein in feline infectious peritonitis (FIP). *Vet Immunol Immunopathol* 2004; **99**: 229–36.
168. Giordano A, Spagnolo V, Colombo A, Paltrinieri S. Changes in some acute phase protein and immunoglobulin concentrations in cats affected by feline infectious peritonitis or exposed to feline coronavirus infection. *Vet J* 2004; **167**: 38–44.
169. Negrin A, Lamb CR, Cappello R, Cherubini GB. Results of magnetic resonance imaging in 14 cats with meningoencephalitis. *J Feline Med Surg* 2007; **9**: 109–16.
170. Tammer R, Evensen O, Lutz H, Reinacher M. Immunohistological demonstration of feline infectious peritonitis virus antigen in paraffin-embedded tissues using feline ascites or murine monoclonal antibodies. *Vet Immunol Immunopathol* 1995; **49**: 177–82.
171. Giordano A, Paltrinieri S, Bertazzolo W, Milesi E, Parodi M. Sensitivity of Tru-cut and fine needle

- aspiration biopsies of liver and kidney for diagnosis of feline infectious peritonitis. *Vet Clin Pathol* 2005; **34**: 368–74.
172. Cotter SM, Hardy Jr WD, Essex M. The association of feline leukemia virus with lymphosarcoma and other disorders. *J Am Vet Med Assoc* 1975; **168**: 448–54.
173. Holmberg CA, Gribble DG. Feline infectious peritonitis: diagnostic gross and microscopic lesions. *Feline Pract* 1973; **3**: 11–4.
174. Kipar A, May H, Menger S, Weber M, Leukert W, Reinacher M. Morphologic features and development of granulomatous vasculitis in feline infectious peritonitis. *Vet Pathol* 2005; **42**: 321–30.
175. Kipar A, Bellmann S, Kremendahl J, Köhler K, Reinacher M. Cellular composition, coronavirus antigen expression and production of specific antibodies in lesions in feline infectious peritonitis. *Vet Immunol Immunopathol* 1998; **65**: 243–57.
176. Kipar A, Köhler K, Leukert W, Reinacher M. A comparison of lymphatic tissues from cats with spontaneous feline infectious peritonitis (FIP), cats with FIP virus infection but no FIP, and cats with no infection. *J Comp Pathol* 2001; **125**: 182–91.
177. Weiss RC, Scott FW. Pathogenesis of feline infectious peritonitis: nature and development of viremia. *Am J Vet Res* 1981; **42**: 382–90.
178. Hickman MA, Morris JG, Rogers QR, Pedersen NC. Elimination of feline coronavirus infection from a large experimental specific pathogen-free cat breeding colony by serologic testing and isolation. *Feline Pract* 1995; **23**: 96–102.
179. Christianson KK, Ingersoll JD, Landon RM, Pfeiffer NE, Gerber JD. Characterization of a temperature-sensitive feline infectious peritonitis coronavirus. *Arch Virol* 1989; **108**: 185–96.
180. Gerber JD, Ingersoll JD, Gast AM, et al. Protection against feline infectious peritonitis by intranasal inoculation of a temperature-sensitive FIPV vaccine. *Vaccine* 1990; **8**: 536–42.
181. Pedersen NC. Basic and clinical immunology. In: Holzworth JE, ed. *Diseases of the cat*. Philadelphia: WB Saunders, 1987: 146–81.
182. Mochizuki M, Mitsutake Y, Miyanohara Y, Higashihara T, Shimizu T, Hohdatsu T. Antigenic and plaque variations of serotype II feline infectious peritonitis coronaviruses. *J Vet Med Sci* 1997; **59**: 253–8.
183. Kiss I, Poland AM, Pedersen NC. Disease outcome and cytokine responses in cats immunized with an avirulent feline infectious peritonitis virus (FIPV)-UCD1 and challenge-exposed with virulent FIPV-UCD8. *J Feline Med Surg* 2004; **6**: 89–97.
184. Stoddart ME, Gaskell RM, Harbour DA, Pearson GR. The sites of early viral replication in feline infectious peritonitis. *Vet Microbiol* 1988; **18**: 259–71.
185. Stoddart ME, Gaskell RM, Harbour DA, Gaskell CJ. Virus shedding and immune responses in cats inoculated with cell culture-adapted feline infectious peritonitis virus. *Vet Microbiol* 1988; **16**: 145–58.
186. Haijema BJ, Volders H, Rottier PJ. Switching species tropism: an effective way to manipulate the feline coronavirus genome. *J Virol* 2003; **77**: 4528–38.
187. Tekes G, Hofmann-Lehmann R, Stallkamp I, Thiel V, Thiel HJ. Genome organization and reverse genetic analysis of a type I feline coronavirus. *J Virol* 2008; **82**: 1851–9.
188. Colgrove DJ, Parker AJ. Feline infectious peritonitis. *J Small Anim Pract* 1971; **12**: 225–32.
189. Hartmann K, Ritz S. Treatment of cats with feline infectious peritonitis. *Vet Immunol Immunopathol* 2008; **123**: 172–5.
190. Weiss RC, Toivio-Kinnucan M. Inhibition of feline infectious peritonitis virus replication by recombinant human leukocyte (alpha) interferon and feline fibroblastic (beta) interferon. *Am J Vet Res* 1988; **49**: 1329–35.
191. Mochizuki M, Nakatani H, Yoshida M. Inhibitory effects of recombinant feline interferon on the replication of feline enteropathogenic viruses in vitro. *Vet Microbiol* 1994; **39**: 145–52.
192. Ishida T, Shibana A, Tanaka S, Uchida K, Mochizuki M. Use of recombinant feline interferon and glucocorticoid in the treatment of feline infectious peritonitis. *J Feline Med Surg* 2004; **6**: 107–9.
193. Ritz S, Egberink H, Hartmann K. Effect of feline interferon-omega on the survival time and quality of life of cats with feline infectious peritonitis. *J Vet Intern Med* 2007; **21**: 1193–7.
194. Zabel P, Schade FU, Schlaak M. Inhibition of endogenous TNF formation by pentoxifylline. *Immunobiology* 1993; **187**: 447–63.
195. Nichols PR, Morris DO, Beale KM. A retrospective study of canine and feline cutaneous vasculitis. *Vet Dermatol* 2001; **12**: 255–64.
196. Pedersen NC. Animal virus infections that defy vaccination: equine infectious anemia, caprine arthritis-encephalitis, maedi-visna, and feline infectious peritonitis. *Adv Vet Sci Comp Med* 1989; **33**: 413–28.
197. Baldwin CW, Scott FW. Attempted immunization of cats with feline infectious peritonitis virus propagated at reduced temperatures. *Am J Vet Res* 1997; **58**: 251–6.
198. Huisman W, Martina BE, Rimmelzwaan GF, Gruters RA, Osterhaus AD. Vaccine-induced enhancement of viral infections. *Vaccine* [Epub ahead of print].
199. Postorino-Reeves N, Coyne MJ, Herman JG. Evaluation of the field efficacy of Primucell-FIP vaccine. *Feline Health Top* 1992; **7**: 6–8.
200. Reeves NC, Pollock RV, Thurber ET. Long-term follow-up study of cats vaccinated with a temperature-sensitive feline infectious peritonitis vaccine. *Cornell Vet* 1992; **82**: 117–23.
201. Wolf AM. Feline infectious peritonitis, part 2. *Feline Pract* 1997; **25**: 24–8.
202. Hoskins JD, Taylor HW, Lomax TL. Challenge trial of an intranasal feline infectious peritonitis vaccine. *Feline Pract* 1994; **22**: 9–13.
203. Fehr D, Holznagel E, Bolla S, et al. Placebo-controlled evaluation of a modified live virus vaccine against feline infectious peritonitis: safety and efficacy under field conditions. *Vaccine* 1997; **15**: 1101–9.
204. Stoddart CA, Barlough JE, Baldwin CA, Scott FW. Attempted immunisation of cats against feline infectious peritonitis using canine coronavirus. *Res Vet Sci* 1988; **45**: 383–8.
205. Woods RD. Efficacy of vaccination of sows with serologically related coronaviruses for control of transmissible gastroenteritis in nursing pigs. *Am J Vet Res* 1984; **45**: 1726–9.
206. Woods RD, Pedersen NC. Cross-protection studies between feline infectious peritonitis and porcine transmissible gastroenteritis viruses. *Vet Microbiol* 1979; **4**: 11–6.
207. Pedersen NC. Virologic and immunologic aspects of feline infectious peritonitis virus infection. *Adv Exp Med Biol* 1987; **218**: 529–50.

208. Vennema H, de Groot RJ, Harbour DA, Horzinek MC, Spaan WJ. Early death after feline infectious peritonitis virus challenge due to recombinant vaccinia virus immunization. *J Virol* 1990; **64**: 1407–9.
209. Wasmoen TL, Kadakia NP, Unfer RC, et al. Protection of cats from infectious peritonitis by vaccination with a recombinant raccoon poxvirus expressing the nucleocapsid gene of feline infectious peritonitis virus. *Adv Exp Med Biol* 1995; **380**: 221–8.
210. Klepfer S, Reed AP, Martinez M, Bhogal B, Jones E, Miller TJ. Cloning and expression of FECV spike gene in vaccinia virus. Immunization with FECVS causes early death after FIPV challenge. *Adv Exp Med Biol* 1995; **380**: 235–41.
211. Glansbeek HL, Haagmans BL, te Lintelo EG, et al. Adverse effects of feline IL-12 during DNA vaccination against feline infectious peritonitis virus. *J Gen Virol* 2002; **83**: 1–10.
212. Hebben M, Duquesne V, Cronier J, Rossi B, Aubert A. Modified vaccinia virus Ankara as a vaccine against feline coronavirus: immunogenicity and efficacy. *J Feline Med Surg* 2004; **6**: 111–8.
213. Hohdatsu T, Yamato H, Ohkawa T, et al. Vaccine efficacy of a cell lysate with recombinant baculovirus-expressed feline infectious peritonitis (FIP) virus nucleocapsid protein against progression of FIP. *Vet Microbiol* 2003; **2**: 31–44.
214. Haijema BJ, Volders H, Rottier PJ. Live, attenuated coronavirus vaccines through the directed deletion of group-specific genes provide protection against feline infectious peritonitis. *J Virol* 2004; **78**: 3863–71.
215. Barlough JE, Scott FW. Effectiveness of three antiviral agents against FIP virus in vitro. *Vet Rec* 1990; **126**: 556–8.
216. Weiss RC, Cox NR, Martinez ML. Evaluation of free or liposome-encapsulated ribavirin for antiviral therapy of experimentally induced feline infectious peritonitis. *Res Vet Sci* 1993; **55**: 162–72.
217. Barnard DL, Day CW, Bailey K, et al. Enhancement of the infectivity of SARS-CoV in BALB/c mice by IMP dehydrogenase inhibitors, including ribavirin. *Antiviral Res* 2006; **71**: 53–63.
218. Barlough JE, Shacklett BL. Antiviral studies of feline infectious peritonitis virus in vitro. *Vet Rec* 1992; **135**: 177–9.
219. Balzarini J, Keyaerts E, Vijgen L, et al. Pyridine N-oxide derivatives are inhibitory to the human SARS and feline infectious peritonitis coronavirus in cell culture. *J Antimicrob Chemother* 2006; **57**: 472–81.
220. Balzarini J, Keyaerts E, Vijgen L, et al. Inhibition of feline (FIPV) and human (SARS) coronavirus by semisynthetic derivatives of glycopeptide antibiotics. *Antiviral Res* 2006; **72**: 20–33.
221. Amici C, DiCoro A, Ciucci A, et al. Indomethacin has a potent antiviral activity against SARS coronavirus. *Antivir Ther* 2006; **11**: 1021–30.
222. Pedersen NC, Addie D, Wolf A. Recommendations from working group of the international coronavirus and feline infectious peritonitis workshop. *Feline Pract* 1995; **23**: 108–11.
223. Corapi WV, Darteil RJ, Audonnet JC, Chappuis GE. Localization of antigenic sites of the S glycoprotein of feline infectious peritonitis virus involved in neutralization and antibody-dependent enhancement. *J Virol* 1995; **69**: 2858–62.
224. Olsen CW, Corapi WV, Ngichabe CK, Baines JD, Scott FW. Monoclonal antibodies to the spike protein of feline infectious peritonitis virus mediate antibody-dependent enhancement of infection of feline macrophages. *J Virol* 1992; **66**: 956–65.
225. Stoddart CA, Scott FW. Intrinsic resistance of feline peritoneal macrophages to coronaviruses correlates with in vivo virulence. *J Virol* 1989; **63**: 436–40.
226. Hohdatsu T, Yamada M, Tominaga R, Makino K, Kida K, Koyama H. Antibody-dependent enhancement of feline infectious peritonitis virus infection in feline alveolar macrophages and human monocyte cell line U937 by serum of cats experimentally or naturally infected with feline coronavirus. *J Vet Med Sci* 1998; **60**: 49–55.
227. Halstead SB. In vivo enhancement of dengue infection with passively transferred antibody. *J Infect Dis* 1979; **140**: 527–33.
228. Halstead SB, Larsen K, Kliks S, Peiris JS, Cardosa J, Porterfield JS. Comparison of P388D-1 mouse macrophage cell line and human monocytes for assay of dengue-2 infection-enhancing antibodies. *Am J Trop Med Hyg* 1983; **32**: 157–63.
229. Halstead SM, Rojanasuphot S, Sangkawibha N. Original antigenic sin in dengue. *Am J Trop Med Hyg* 1983; **32**: 154–6.
230. Peiris JSM, Porterfield JS. Antibody-mediated enhancement of flavivirus replications in macrophage-like cell lines. *Nature* 1979; **28**: 507–11.
231. Peiris JSM, Gordon S, Unkeless JC, Porterfield JS. Monoclonal anti-Fc receptor IgG blocks antibody enhancement of viral replication in macrophages. *Nature* 1981; **289**: 189–91.
232. Porterfield JS. Immunological enhancement and the pathogenesis of dengue hemorrhagic fever. *J Hyg* 1982; **89**: 355–64.
233. Gonon V, Duquesne V, Klonjowski B, Monteil M, Aubert A, Eloit M. Clearance of infection in cats naturally infected with feline coronaviruses is associated with an anti-S glycoprotein antibody response. *J Gen Virol* 1999; **80**: 2315–7.
234. Takano T, Azuma N, Hashida Y, Satoh R, Hohdatsu T. B-cell activation in cats with feline infectious peritonitis (FIP) by FIP-virus-induced B-cell differentiation/survival factors. *Arch Virol* [Epub ahead of print].
235. Takano T, Katada Y, Moritoh S, et al. Analysis of the mechanism of antibody-dependent enhancement of feline infectious peritonitis virus infection: aminopeptidase N is not important and a process of acidification of the endosome is necessary. *J Gen Virol* 2008; **89**: 1025–9.
236. Paltrinieri S, Cammarata Parodi M, Cammarata G, Mambretti M. Type IV hypersensitivity in the pathogenesis of FIPV-induced lesions. *Zentralblatt Vet Med B* 1989; **45**: 151–9.
237. Hardy Jr WD. Immunopathology induced by the feline leukemia virus. *Springer Semin Immunopathol* 1982; **5**: 75–106.
238. de Groot-Mijnes JD, van Dun JM, van der Most RG, de Groot RJ. Natural history of a recurrent feline coronavirus infection and the role of cellular immunity in survival and disease. *J Virol* 2005; **79**: 1036–44.
239. Paltrinieri S, Ponti W, Comazzi S, Giordano A, Poli G. Shifts in circulating lymphocyte subsets in cats with feline infectious peritonitis (FIP): pathogenic role and diagnostic relevance. *Vet Immunol Immunopathol* 2003; **15**: 141–8.
240. Pedersen NC, Evermann JF, McKeirnan AJ, Ott RL. Pathogenicity studies of feline coronavirus isolates 79-1146 and 79-1683. *Am J Vet Res* 1984; **45**: 2580–5.

241. Takano T, Hohdatsu T, Hashida Y, Kaneko Y, Tanabe M, Koyama H. A 'possible' involvement of TNF-alpha in apoptosis induction in peripheral blood lymphocytes of cats with feline infectious peritonitis. *Vet Microbiol* 2007; **119**: 121–31.
242. Takano T, Hohdatsu T, Toda A, Tanabe M, Koyama H. TNF-alpha, produced by feline infectious peritonitis virus (FIPV)-infected macrophages, upregulates expression of type II FIPV receptor feline aminopeptidase N in feline macrophages. *Virol* 2007; **364**: 64–72.
243. Berg AL, Ekman K, Belák S, Berg M. Cellular composition and interferon-gamma expression of the local inflammatory response in feline infectious peritonitis (FIP). *Vet Microbiol* 2005; **111**: 15–23.
244. Dean GA, Olivry T, Stanton C, Pedersen NC. In vivo cytokine response to experimental feline infectious peritonitis virus infection. *Vet Microbiol* 2003; **97**: 1–12.
245. Foley JE, Rand C, Leutenegger C. Inflammation and changes in cytokine levels in neurological feline infectious peritonitis. *J Feline Med Surg* 2003; **5**: 313–22.
246. Gunn-Moore DA, Caney SM, Gruffydd-Jones TJ, Helps CR, Harbour DA. Antibody and cytokine responses in kittens during the development of feline infectious peritonitis (FIP). *Vet Immunol Immunopathol* 1988; **23**: 221–42.
247. Regan AD, Cohen RD, Whittaker GR. Activation of p38 MAPK by feline infectious peritonitis virus regulates pro-inflammatory cytokine production in primary blood-derived feline mononuclear cells. *Virol* [Epub ahead of print].
248. Gelain ME, Meli M, Paltrinieri S. Whole blood cytokine profiles in cats infected by feline coronavirus and healthy non-FCoV infected specific pathogen-free cats. *J Feline Med Surg* 2006; **8**: 389–99.
249. Kipar A, Baptiste K, Barth A, Reinacher M. Natural FCoV infection: cats with FIP exhibit significantly higher viral loads than healthy infected cats. *J Feline Med Surg* 2006; **8**: 69–72 [Epub 2005].
250. Martin ML. Coronavirus enteritis and a recent outbreak following modified live virus vaccination. *Compend Cont Educ Pract Vet* 1985; **7**: 1012–7.
251. Woods RD, Cheville NF, Gallagher JE. Lesions in the small intestine of newborn pigs inoculated with porcine, feline, and canine coronaviruses. *Am J Vet Res* 1981; **42**: 1163–9.
252. Shi Z, Hu Z. A review of studies on animal reservoirs of the SARS coronavirus. *Virus Res* 2008; **133**: 74–87 [Epub 2007].
253. Wang LF, Eaton BT. Bats, civets and the emergence of SARS. *Curr Top Microbiol Immunol* 2007; **315**: 325–44.
254. Oostra M, de Haan CA, Rottier PJ. The 29-nucleotide deletion present in human but not in animal severe acute respiratory syndrome coronaviruses disrupts the functional expression of open reading frame 8. *J Virol* 2007; **81**: 13876–88.
255. Nagata N, Iwata N, Hasegawa H, et al. Participation of both host and virus factors in induction of severe acute respiratory syndrome (SARS) in F344 rats infected with SARS coronavirus. *J Virol* 2007; **81**: 1848–57 [Epub 2006].
256. Garner MM, Ramsell K, Morera N, et al. Clinicopathologic features of a systemic coronavirus-associated disease resembling feline infectious peritonitis in the domestic ferret (*Mustela putorius*). *Vet Pathol* 2008; **45**: 236–46.
257. Perpiñán D, López C. Clinical aspects of systemic granulomatous inflammatory syndrome in ferrets (*Mustela putorius furo*). *Vet Rec* 2008; **162**: 180–4.
258. Martínez J, Ramis AJ, Reinacher M, Perpiñán D. Detection of feline infectious peritonitis virus-like antigen in ferrets. *Vet Rec* 2006; **158**: 523.
259. Addie DD, Schaap IA, Nicolson L, Jarrett O. Persistence and transmission of natural type I feline coronavirus infection. *J Gen Virol* 2003; **84**: 2735–44.
260. Addie DD, Paltrinieri S, Pedersen NC. Recommendations of the second international feline coronavirus/feline infectious peritonitis symposium. *J Feline Med Surg* 2004; **6**: 125–30.